



Autosomal dominant polycystic kidney disease

V. E. Torres and P. C. Harris

Division of Nephrology. Mayo Clinic. Rochester, MN.

INTRODUCTION

Autosomal dominant polycystic kidney disease (ADPKD) is a multisystem disorder characterized by a) bilateral renal cysts; b) cysts in other organs, such as the liver, seminal vesicles, pancreas, and arachnoid membrane; c) extrarenal abnormalities, such as intracranial aneurysms and dolichoectasias, dilatation of the aortic root and dissection of the thoracic aorta, mitral valve prolapse, and abdominal wall hernias, and d) the absence of manifestations suggestive of a different renal cystic disease¹. It is a very common disease, with an estimated prevalence of 1:400 to 1:1,000 live births^{2,3}, and the third most common cause of end stage renal failure worldwide⁴.

GENETICS

Linkage studies have shown that ADPKD is genetically heterogeneous with two disease loci mapped and identified, on chromosomes 16 (*PKD1*) and 4 (*PKD2*)⁵⁻⁸. A number of unlinked families have also been identified, suggesting the existence of a further locus⁹⁻¹¹. However, the lack of progress toward mapping this locus and the description of a family cosegregating *PKD1* and *PKD2*, with a resulting complex disease pattern, has cast doubt on the existence of a third gene¹². *PKD1* and *PKD2* are clinically similar diseases with polycystic liver disease and ICAs described in both cases^{13,14}. However, there is an important difference in terms of the severity of renal disease, with the average age at the onset of ESRD of 53 years for *PKD1* and 69 years for *PKD2*¹⁵.

The *PKD1* gene transcribes a large transcript of over 14kb and encodes a protein, polycystin-1, of 4,302aa^{6,7}. Polycystin-1 is an integral membrane pro-

tein with 11 transmembrane domains, a short cytoplasmic tail and large extracellular region^{7,16}. The extracellular part of the protein has homology to many recognized domains which are usually involved in protein-protein or protein-carbohydrate interactions (See fig. 1 for details). Almost 1,400 bp of this region is occupied by 16 PKD repeats, a domain with an immunoglobulin-like fold¹⁷. Significant homology of ~1,000aa is also found with a family of sperm expressed sea urchin proteins that are involved in sperm/egg interactions and triggering the acrosome reaction^{18,19}. The overall structure of polycystin-1 suggests a role in cell:cell and/or cell:matrix interactions²⁰⁻²⁴. The C-terminal tail of polycystin-1 has previously been shown to interact with the corresponding region of polycystin-2 and a variety of other proteins^{25,26}, has been shown to tether the protein to the cytoskeleton²⁴, may bind G proteins²⁷ and activate Gi/o-type proteins²⁸.

The *PKD2* transcript is 5.5kb and encodes a 968aa protein, polycystin-2⁸. Polycystin-2 is predicted to have cytoplasmic N- and C-termini and 6 transmembrane domains⁸ (See fig. 1 for details). The transmembrane region is homologous to polycystin-1 and also voltage activated and transient receptor potential (TRP) channel subunits²⁹. Recently, functional studies have indicated that the polycystins may act as Ca²⁺-permeable cation channels³⁰⁻³². The physiological location of polycystin-2 (and -1) and the characteristics of the channel require further study. Nevertheless, the likelihood that the normal role of polycystin-2 is in Ca²⁺ transport and that polycystin-1 may have a regulatory role in this process provide the best clues to the basic defect in ADPKD. A location for polycystin-2 on the plasma membrane or ER could be consistent with a role in modulating intra-cellular levels of Ca²⁺, either allowing entry of extra-cellular Ca²⁺ or release of Ca²⁺ from intracellular stores^{29,33}. Therefore, binding an unknown ligand to the extracellular region of polycystin-1 may activate a polycystin Ca²⁺ permeable channel. A transient and localized increase in Ca²⁺ levels could effect many pathways given the known second messenger function of Ca²⁺. In the disease state mutation to *PKD1* or *PKD2* (and a possible second hit

Correspondence: Dr. Vicente E. Torres
Mayo Foundation
200 First Street SW
Rochester, MN 55901
E-mail: torres.vicente@mayo.edu

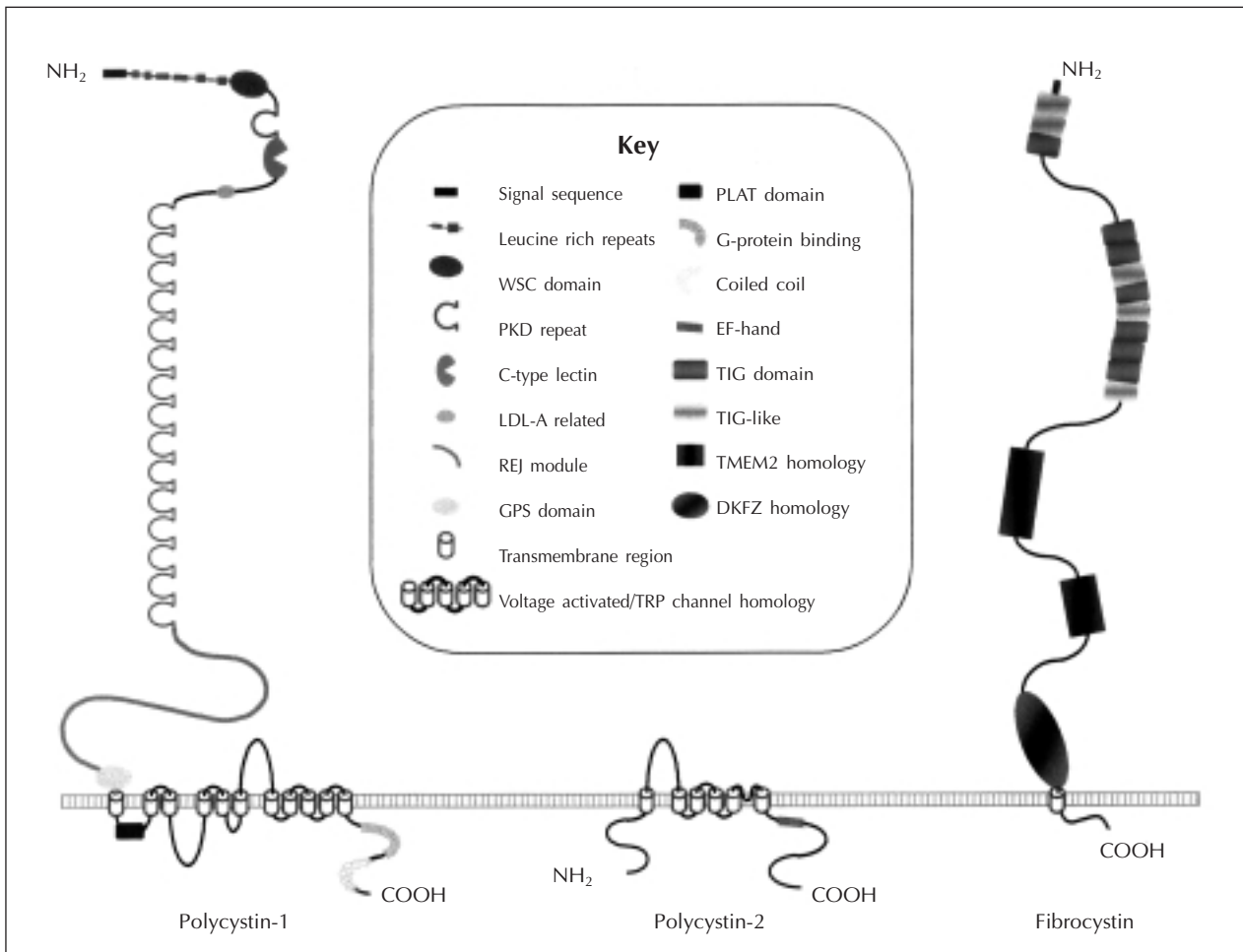


Fig. 1.—Models of the ADPKD proteins, polycystin-1 and polycystin-2 and the ARPKD protein, fibrocystin. Conserved domains and regions of homology with other proteins are shown (see key for details).

somatic mutation³⁴) could lead to loss of functional channels, production of unregulated channels or the generation of channels that leak Ca^{2+} into the cytoplasm.

One aspect of ADPKD research that has proceeded slowly is mutation analysis because of the complex duplicated region encoding *PKD1*^{5,35}. However, in the past 18 months several reports have shown schemes for specific amplification of *PKD1* that have allowed complete mutation analysis of this gene³⁶⁻³⁸. In particular, DHPLC methods make routine screening for mutation in *PKD1* and *PKD2* a possibility, with a detection levels of 60-70%³⁷. These studies have confirmed earlier findings that a wide range of different mutations cause PKD1 and that most families have unique changes, indicating a significant

level of new mutation. Mutations are spread throughout the gene but are significantly more frequent in the 3' half³⁶. Initial analysis of possible genotype/phenotype correlations have indicated considerable intrafamilial phenotypic variability, in terms of the severity of renal disease, as suggested by previous clinical studies^{39,40} and may be partly due to modifying loci or environmental factors. Nevertheless, evidence for a correlation between the site of the mutation and the age at onset of ESRD was detected, with mutations in the 5' half of the gene associated with more severe disease⁴¹. The reason for this phenotype difference is not clear but may be associated with the production of more than one polycystin-1 product from *PKD1* due to cleavage or alternative splicing⁴².

PATHOLOGY AND PATHOGENESIS

ADPKD kidneys are typically enlarged and diffusely cystic, but in early stages they may be of normal size and with a limited number of macroscopic cysts scattered in the cortex and medulla⁴³. Microdissection and histologic studies have shown that cysts develop as outpouchings along a limited number of nephrons and collecting ducts. Analysis of X-chromosome inactivation patterns in epithelial cells isolated from individual supports their derivation from clonal expansion of single cells⁴⁴. The genetic events initiating this clonal transformation include loss of heterozygosity or a somatic mutation of the allele unaffected by the germline mutation or possibly somatic mutations of other related genes. The cyst-derived epithelial cells are characterized by a partially dedifferentiated phenotype and an abnormal proliferative response to cyclic AMP agonists that normally inhibit proliferation in the renal tubular epithelial cells⁴⁵⁻⁴⁸. When the cysts reach ~2 mm in diameter, they become disconnected from the tubules. Accumulation of fluid within these cysts occurs by chloride driven fluid secretion which is also stimulated by cyclic AMP⁴⁹. Microscopically, the cysts are characterized by nonpolypoid and by polypoid hyperplasia of the epithelium⁵⁰. Despite the frequency of hyperplastic lesions and microscopic adenomas, the incidence of renal cell carcinoma does not appear to be increased, possibly due to the coexisting enhanced rate of apoptosis, or programmed cell death⁵¹. The tubular basement membranes surrounding the cysts are typically thickened and often laminated. The adjacent parenchyma is compressed. Interstitial fibrosis is a prominent finding, even in patients with early disease. It is associated with inflammatory infiltrates consisting of macrophages and lymphocytes. Vascular sclerosis involving both afferent arterioles and interlobular arteries is also prominent.

CLINICAL DIAGNOSIS

Symptomatic subjects, regardless of age, usually benefit from having a specific diagnosis established. At-risk asymptomatic adult family members may seek testing in order to make personal decisions or to satisfy their «need to know». Those seeking testing should be counseled about possible problems they may encounter with regards to health, life, and disability insurance coverage, employment discrimination, and changes in social and family interaction. Consensus holds that children at risk for adult-onset disorder should not have testing in the absence of

symptoms. Prenatal testing for ADPKD is possible using molecular genetic techniques after the mutation has been identified in an affected family member or if linkage has been established in the family. However, only 4% of ADPKD patients or their spouses would terminate a pregnancy for ADPKD⁵² and consequently, requests for prenatal testing are rare.

The diagnosis of ADPKD is established primarily by imaging studies of the kidneys; however, molecular genetic testing can be used if the imaging results are equivocal or if a definite diagnosis in a young person (less than 30 years) is required, as for a potential renal transplant donor. Molecular genetic testing is not useful in predicting age of onset, severity, type of symptoms, or rate of progression of the disease.

Sonographic diagnostic criteria have been established for individuals known to be at 50% risk for the disease⁵³. They include at least 2 cysts either unilateral or bilateral in patients less than age 30 years, two cysts in each kidney in patients age 30-59 years, and four cysts in each kidney in patients age 60 years or older. The sensitivity of these criteria is nearly 100% for all patients with ADPKD who are age 30 years or older and for younger patients with *PKD1* mutations, but these criteria are only 67% sensitive for patients with *PKD2* mutations who are younger than age 30 years⁵⁴. Large echogenic kidneys without distinct macroscopic cysts in an infant/child at 50% risk for ADPKD are diagnostic. In the absence of a family history of ADPKD, the presence of bilateral renal enlargement and cysts, with or without the presence of hepatic cysts, and the absence of other manifestations suggestive of a different renal cystic disease provide presumptive, but not definite, evidence for the diagnosis.

Molecular genetic testing can be performed using linkage analysis or direct mutation *screening*. Linkage analysis with highly informative microsatellite markers flanking the *PKD1* and *PKD2* genes is possible in large families with several affected family members willing to be tested. Linkage testing is not available to small families or families with a single affected individual and it may be complicated if a *de novo* mutation has occurred recently in the family. The large size and complexity of the *PKD1* gene, as well as marked allelic heterogeneity, present obstacles to molecular testing by mutation analysis. Recently, clinical testing of the *PKD1* and *PKD2* genes by direct sequencing analysis has become available, but the detection rate for disease-causing mutations is not yet known^{36,37}. Mutation-based approaches have the advantage that only a single sample needs to be examined and, once a

mutation is identified within a family, testing of other at-risk family members is straightforward. However, the large number of different mutations and wide array of polymorphisms described for the *PKD1* gene mean that care is required in interpretation of results to differentiate pathogenic changes from neutral polymorphisms^{36,37}.

RENAL MANIFESTATIONS

The renal manifestations of ADPKD include renal function abnormalities, hypertension, renal pain, and renal insufficiency. Reduction in urinary concentrating capacity and excretion of ammonia may occur early and result from the disruption of the renal architecture by the cysts, interference with the countercurrent exchange and multiplication mechanisms, and defective trapping of solutes and ammonia in the renal medulla. Although the concentrating defect may not have clinical consequences, the reduction of urinary excretion of ammonia in the presence of metabolic stresses, such as dietary indiscretions, may contribute to the development of uric acid and calcium oxalate stones, which, in association with low urine pH values and hypocitric aciduria, occur with increased frequency in ADPKD^{55,56}.

Another early functional abnormality is a reduction in renal blood flow, which can be detected in young patients, when blood pressures are still normal and before any decline in glomerular filtration rate (GFR). It is characterized by an increase in renal vascular resistance and filtration fraction; high sympathetic nerve activity; normal or high peripheral plasma renin activity; reduced nitric oxide synthesis; resetting of the pressure-natriuresis relationship; salt sensitivity; normal or increased extracellular fluid volume, plasma volume, and cardiac output and partial correction of renal hemodynamics and sodium handling by converting-enzyme inhibition⁵⁷. Hypertension in ADPKD may lead to end-organ damage, may increase the morbidity and mortality from associated vascular and cardiac defects and may cause fetal and maternal complications during pregnancy⁵⁸.

Pain is a common manifestation of ADPKD⁵⁹. Potential etiologies include cyst hemorrhage, nephrolithiasis, cyst infection, and rarely, tumor. Discomfort, ranging from a sensation of fullness to severe pain, can also result from renal enlargement and distortion by the cysts. Gross hematuria can occur in association with complications such as cyst hemorrhage and nephrolithiasis or as an isolated event. Passage of clots can also be a source of pain. A cyst hemorrhage can be accompanied by fever. Most

often the pain is self-limited and resolves within 2-7 days. Rarely, pain may result from retroperitoneal bleeding, which may be severe and require transfusion. The prevalence of renal stone disease in patients with ADPKD is approximately 20%⁵⁵. The majority of stones are composed of uric acid and/or calcium oxalate. Urinary stasis thought to be secondary to distorted renal anatomy and metabolic factors play a role in the pathogenesis. In the past, the incidence of urinary tract infection may have been overestimated in ADPKD because of the frequent occurrence of sterile pyuria. Females experience urinary tract infection more frequently than males and the majority of infections are caused by *E. coli* and other enterobacteriaceae. Massive renal enlargement can cause complications resulting from compression of local structures, such as inferior vena cava compression and gastric outlet obstruction (mainly by right renal cysts). Approximately 50% of patients with ADPKD have end-stage renal disease (ESRD) at about age 60 years¹. Once renal insufficiency has begun, the average yearly rate of decline in GFR is approximately 5 ml/min⁶⁰. Compression of the normal renal parenchyma by expanding cysts, vascular sclerosis, interstitial inflammation and fibrosis, and apoptosis of the tubular epithelial cells are the causative mechanisms. Smoking and the presence of hypertension, hyperlipidemia and proteinuria are associated with an increased risk for disease progression⁶¹.

EXTRARENAL MANIFESTATIONS

The prevalence of liver cysts in patients with ADPKD increases from 20% in the third decade to approximately 75% after the sixth decade⁶². Polycystic liver disease develops at a younger age in women and is more severe in those who have had multiple pregnancies. After menopause, the size of the liver cysts increases in those women who receive estrogen replacement therapy, an observation which suggests that estrogens have an important effect on the progression of polycystic liver disease⁶³. Liver cysts are usually asymptomatic and never cause liver failure. Symptoms, when they occur, are caused by the mass effect of the cysts, the development of complications, or rare associations. Mass effects include abdominal distention and pain, early satiety, dyspnea and low back pain. Liver cysts can also cause extrinsic compression of the inferior vena cava (IVC), hepatic veins, or bile ducts⁶⁴. Complications of polycystic liver disease include cyst hemorrhage, infection, or rupture. Hemorrhagic cysts may cause fever and masquerade as cholecystitis or cyst infec-

tion. Infected cysts cause localized pain or tenderness, fever, leukocytosis, elevated erythrocyte sedimentation rate, and high serum concentration of alkaline phosphatase⁶⁵. The rupture of a hepatic cyst can cause acute abdominal pain and ascites. Dilatation of biliary ducts may be associated with episodes of cholangitis. Congenital hepatic fibrosis is very rare in ADPKD and, contrary to the cystic disease, is not transmitted in an autosomal dominant manner. Cholangiocarcinoma is infrequently associated with ADPKD.

The most important non-cystic manifestations of ADPKD include intracranial arterial aneurysms and dolichoectasias, dilatation of the aortic root, dissection of the thoracic aorta and cervicocephalic arteries, abnormalities of the cardiac valves, and possibly coronary artery aneurysms⁶⁶. Mitral valve prolapse is the most common valvular abnormality. Common to these vascular and cardiac lesions is the disruption of the connective tissue framework responsible for their mechanical properties. It seems likely that the PKD mutations are directly responsible for the vascular and cardiac manifestations of ADPKD, since polycystin and polycystin-2 are strongly expressed in the medial myocytes of elastic and large distributive arteries, as well as in the cardiac myocytes and valvular myofibroblasts^{67,68}.

Intracranial aneurysms occur in approximately 10% of individuals with ADPKD⁶⁶. The prevalence is higher in those with a positive family history of intracranial or subarachnoid hemorrhage (22%) than in those without (6%). The majority of intracranial aneurysms are asymptomatic. Focal findings such as cranial nerve palsy or seizure may result from compression of local structures by an enlarging aneurysm. The risk of rupture of asymptomatic intracranial aneurysms depends on whether there is a history of rupture from a different site⁶⁹. In the absence of such history the risk is 0.05% per year for aneurysms less than ten mm, about 1% per year from aneurysms measuring 10-24 mm, and 6% within one year for those measuring 25 mm or more in diameter. When there is a previous history of rupture from a different site, the risk of rupture is 0.5-1% per year regardless of size. The risk of rupture of symptomatic aneurysms is higher, approximately 4% per year. Rupture carries a 35-55% risk of combined severe morbidity and mortality at three months⁷⁰.

MANAGEMENT

Current therapy is directed towards reducing the morbidity and mortality from the renal and extrarenal complications of the disease.

The antihypertensive agent(s) of choice in ADPKD has not been clearly established. Because of the role of the renin angiotensin system in the pathogenesis of hypertension in this disease, ACE inhibitors and angiotensin II receptor antagonists may be superior to other agents in patients with preserved renal function. ACE inhibitors, angiotensin II antagonists, and calcium channel blockers increase renal blood flow, have a low side effect profile, and may reduce vascular smooth muscle proliferation and development of atherosclerosis. The administration of ACE inhibitors, but not the administration of calcium channel blockers, has been shown to reduce microalbuminuria in patients with ADPKD⁵⁷. In a historical non-randomized study, the administration of ACE inhibitors without diuretics was found to result in a lower rate of decline in GFR and less proteinuria than the administration of a diuretic without an ACE inhibitor for similar control of blood pressure⁵⁷.

Episodes of cyst hemorrhage or of gross hematuria are self-limited and respond well to conservative management with bed rest, analgesics, and adequate hydration. Rarely, episodes of bleeding are more severe with extensive subcapsular or retroperitoneal hematoma, significant drop in hematocrit, and hemodynamic instability. Such patients require hospitalization, transfusion, and investigation by CT or angiography. In cases of unusually severe or persistent hemorrhage, segmental arterial embolization or surgery may be required. Gross hematuria persisting more than one week or developing for the first time in a patient older than age 50 years requires thorough investigation.

The treatment of nephrolithiasis in patients with ADPKD is not different from that in patients without ADPKD. Potassium citrate is the treatment of choice in three conditions associated with ADPKD: uric acid lithiasis, hypocitric calcium oxalate nephrolithiasis, and distal acidification defects⁵⁵. Extracorporeal shock-wave lithotripsy and percutaneous nephrostolithotomy can be successful in patients with ADPKD without excessive complications.

If cyst infection is suspected, diagnostic imaging should be undertaken to assist in the diagnosis. CT and magnetic resonance imaging (MRI) are sensitive for detecting complicated cysts and provide anatomic definition, but the findings are not specific for infection. Nuclear imaging, especially indium-labeled white cell scanning, is useful, but false-negative and false-positive results are possible. In the appropriate clinical setting, cyst aspiration under ultrasound or CT-guidance should be undertaken to culture the organism and assist in selection of antimicrobial therapy.

Cyst infection is often difficult to treat. It has a high treatment failure rate despite prolonged therapy with an antibiotic to which the organism is susceptible. Treatment failure results from the inability of certain antibiotics to penetrate the cyst epithelium successfully and achieve therapeutic concentrations within the cysts⁷¹. Lipophilic agents have been shown to penetrate all cysts and have a pKa that allows for favorable electrochemical gradients into acidic cyst fluids. Therapeutic agents of choice include trimethoprim-sulfamethoxazole and fluoroquinolones. Chloramphenicol has shown therapeutic efficacy in otherwise refractory disease. If fever persists after 1-2 weeks of appropriate antimicrobial therapy, percutaneous or surgical drainage of infected cysts should be undertaken. If fever recurs after stopping antibiotics, complicating features, such as obstruction, perinephric abscess, or stones should be considered and treated appropriately. If complicating features are not identified, the course of previously effective therapy should be extended and several months may be required to eradicate infection fully.

After excluding causes of flank pain that may require intervention, such as infection, stone, or tumor, an initial conservative approach to pain management is best⁵⁹. Nonopioid agents are preferred and care should be taken to avoid long-term administration of nephrotoxic agents such as combination analgesic and nonsteroidal anti-inflammatory drugs. Tricyclic antidepressants are helpful, as in all chronic pain syndromes, and are well tolerated. The use of narcotic analgesics should be reserved for the management of acute episodes, as chronic use can lead to physical and psychologic dependence. Splanchnic nerve blockade with local anesthetics or steroids can result in pain relief beyond the duration of the local anesthetic.

When conservative measures fail, therapy can be directed toward cyst decompression with cyst aspiration and sclerosis, surgical cyst decompression, or laparoscopic cyst decompression⁵⁹. Cyst aspiration, under ultrasound or CT guidance, is a relatively simple procedure carried out routinely by interventional radiologists. To prevent the reaccumulation of cyst fluid, sclerosing agents such as 95% ethanol or acidic solutions of minocycline are commonly used. In patients with many cysts contributing to pain, laparoscopic or surgical cyst fenestration through lumbotomy or flank incision may be of benefit. Surgical intervention does not accelerate the decline in renal function, but neither does it appear to preserve declining renal function. Laparoscopic fenestration has been shown to be equally effective as open surgical fenestration in short-term follow-up for patients with limited disease, and has a shorter, less complicated

recovery period. Recently, laparoscopic and retroperitoneoscopic nephrectomy and arterial embolization have been used to treat symptomatic polycystic kidneys in ADPKD patients with ESRD^{72,73}.

Therapeutic interventions aimed at slowing the progression of renal failure in ADPKD include control of hypertension and hyperlipidemia, dietary protein restriction, control of acidosis, and prevention of hyperphosphatemia. Animal data support the role of dietary protein restriction and careful control of hypertension in slowing the rate of renal failure in PKD⁷⁴. The Modification of Diet in Renal Disease (MDRD) trial, however, showed no beneficial effect on renal function of strict, compared with standard, blood pressure control and only a slight beneficial effect of borderline significance of a very low protein diet⁶⁰. Since these interventions were introduced at a late state of the disease (GFR 13-55 mL/min per 1.73 m²), these results do not exclude a beneficial effect of earlier interventions.

Most patients with polycystic liver disease have no symptoms and require no treatment⁶². The treatment of symptomatic disease includes the avoidance of estrogens and the use of H₂ blockers or proton pump inhibitors for symptomatic relief. Somatostatin analogues and estrogen antagonists have not been beneficial in small trials or anecdotal reports. Severe symptoms may require percutaneous aspiration and sclerosis, laparoscopic fenestration, combined hepatic resection and cyst fenestration, or liver transplantation. Any of these interventions should be tailored to individual patients. Cyst aspiration and sclerosis with alcohol or minocycline is the treatment of choice for symptoms caused by one or a small number of dominant cysts. There is less experience with laparoscopic fenestration of hepatic cysts. This procedure is complicated by transient ascites in 40% of patients, and the results are often short-lived. Neither percutaneous sclerosis nor laparoscopic fenestration is helpful in highly symptomatic patients with large polycystic livers with many small- and medium-sized cysts. In most cases, part of the liver is spared, allowing treatment by combined hepatic resection and cyst fenestration. The surgery and recovery from this procedure can be difficult, with complications such as transient ascites and bile leaks and a perioperative mortality of 3%. Only specialized centers and surgeons experienced in this surgery should perform this procedure. This surgery has good long-term results in subjects with severe polycystic liver disease. Liver transplantation is reserved for those rare patients without spared segments of liver parenchyma or with hepatic insufficiency⁷⁵.

Widespread *screening* for intracranial aneurysms is not cost effective or indicated because most found by

screening asymptomatic patients are small, have a low risk of rupture, and require no treatment⁶⁶. Indications for *screening* in 20-50 year-old patients with a good life expectancy include family history of intracranial aneurysms or subarachnoid hemorrhage, previous aneurysmal rupture, preparation for elective surgery with potential hemodynamic instability, high-risk occupations such as airplane pilots, and significant anxiety on the part of the patient despite adequate risk information. Magnetic resonance angiography is the diagnostic imaging modality of choice for presymptomatic screening, as it is noninvasive and does not require intravenous contrast material.

For ruptured or symptomatic intracranial aneurysm, the mainstay of therapy is surgical clipping of the ruptured aneurysm at its neck. Asymptomatic aneurysms measuring five mm in diameter or less, diagnosed by presymptomatic screening, can be observed and followed initially at yearly intervals. If the size increases, surgery is indicated. The management of aneurysms between six and nine mm remains controversial. Surgical intervention is usually indicated for unruptured aneurysms measuring ten mm in diameter or greater. For patients with high surgical risk or with technically difficult-to-manage lesions, endovascular treatment with detachable platinum coils may be indicated. Endovascular treatment seems to be associated with fewer complications than clipping, but the long-term efficacy of this method is, as yet, unproved⁶⁶.

REFERENCES

- Gabow P: Autosomal dominant polycystic kidney disease. *N Engl J Med* 329: 323-342, 1993.
- Dalgaard OZ: Bilateral polycystic disease of the kidneys: a follow-up of two hundred and eighty-four patients and their families. *Acta Med Scand* 328 (Supl.): 1-255, 1957.
- Iglesias CG, Torres VE, Offord KP, Holley KE, Beard CM, Kurland LT: Epidemiology of adult polycystic kidney disease, Olmsted County, Minnesota. *Am J Kid Dis* 2: 630-639, 1983.
- Cooper L: USRDS, 2001 Annual Data Report. *Nephrol News Issues* 15: 34-38, 2001.
- European Polycystic Kidney Disease Consortium: The polycystic kidney disease 1 gene encodes a 14 kb transcript and lies within a duplicated region on chromosome 16. *Cell* 77: 881-894, 1994.
- International Polycystic Kidney Disease Consortium: The complete structure of the PKD1 gene and its protein. *Cell* 81: 289-298, 1995.
- Hughes J, Ward CJ, Peral B, et al.: The polycystic kidney disease 1 (PKD1) gene encodes a novel protein with multiple cell recognition domains. *Nature Genet* 10: 151-160, 1995.
- Mochizuki T, Wu G, Hayashi T, et al.: PKD2, a gene for polycystic kidney disease that encodes an integral membrane protein. *Science* 272: 1339-1342, 1996.
- Daoust MC, Reynolds DM, Bichet DG, Somlo S: Evidence for a third genetic locus for autosomal dominant polycystic kidney disease. *Genomics* 25: 733-736, 1995.
- de Almeida S, de Almeida E, Peters D, et al.: Autosomal dominant polycystic kidney disease: evidence for the existence of a third locus in a Portuguese family. *Hum Genet* 96: 83-88, 1995.
- De Almeida E, Prata MM, De Almeida S, Lavinha J: Long-term follow-up of a family with autosomal dominant polycystic kidney disease type 3. *Nephrol Dial Transplant* 14: 631-634, 1999.
- Pei Y, Paterson AD, Wang KR, et al.: Bilineal disease and trans-heterozygotes in autosomal dominant polycystic kidney disease. *Am J Hum Genet* 68: 355-363, 2001.
- Torra R, Badenas C, Darnell A, et al.: Linkage, clinical features, and prognosis of autosomal dominant polycystic kidney disease types 1 and 2. *J Am Soc Nephrol* 7: 2142-2151, 1996.
- Van Dijk MC, PC. Peters, DJ. Breuning, MH: Intracranial aneurysms in polycystic kidney disease linked to chromosome 4. *J Am Soc Neph* 6 (6): 1670-1673, 1995.
- Hateboer N, Van Dijk M, Bogdanova N, et al.: Comparison of phenotypes of polycystic kidney disease types 1 and 2. *Lancet* 353: 103, 1999.
- Sandford R, Sgotto B, Aparacio S, et al.: Comparative analysis of the polycystic kidney disease 1 (PKD1) gene reveals an integral membrane glycoprotein with multiple evolutionary conserved domains. *Hum Mol Genet* 6 (9): 1483-1489, 1997.
- Bycroft M, Bateman A, Clarke J y cols.: The structure of a PKD domain from polycystin-1: implication for polycystic kidney disease. *EMBO Journal* 18: 297-305, 1999.
- Moy GW, Mendoza LM, Schulz JR, Swanson WJ, Glabe CG, Vacquier VD: The sea urchin sperm receptor for egg jelly is a modular protein with extensive homology to the human polycystic kidney disease protein, PKD1. *J Cell Biol* 133 (4): 809-817, 1996.
- Mengerink KJ, Moy GW, Vacquier VD: suREJ3, a polycystin-1 protein, is cleaved at the GPS domain and localizes to the acrosomal region of sea urchin sperm. *J Biol Chem* 277 (2): 943-948, 2002.
- Huan Y, Van Adelsberg J: Polycystin-1, the PKD1 gene product, is in a complex containing E-cadherin and the catenins. *J Clin Invest* 104 (10): 1459-1468, 1999.
- Wilson P, Geng L, Li X, Burrow C: The PKD1 gene product, «Polycystin-1», is a tyrosine-phosphorylated protein that co-localizes with alpha 2 beta 1-integrin in focal clusters in adherent renal epithelia. *Lab Invest* 79 (10): 1311-1323, 1999.
- Ibraghimov-Beskrovnaya O, Bukanov NO, Donohue LC, Dackowski WR, Klinger KW, Landes GM: Strong homophilic interactions of the Ig-like domains of polycystin-1, the protein product of an autosomal dominant polycystic kidney disease gene, PKD1. *Hum Mol Genet* 9 (11): 1641-1649, 2000.
- Scheffers MS, Van der Bent P, Prins F, et al.: Polycystin-1, the product of the polycystic kidney disease 1 gene, co-localizes with desmosomes in MDCK cells. *Hum Mol Genet* 9 (18): 2743-2750, 2000.
- Xu GM, Sikaneta T, Sullivan BM, et al.: Polycystin-1 interacts with intermediate filaments. *J Biol Chem* 276 (49): 46544-46552, 2001.
- Qian F, Germino FJ, Cai Y, Zhang X, Somlo S, Germino GG: PKD1 interacts with PKD2 through a probable coiled-coil domain. *Nature Genet* 16: 179-183, 1997.
- Tsiokas L, Kim E, Arnould T, Sukhatme VP, Walz G: Homo- and heterodimeric interactions between the gene products of PKD1 and PKD2. *Proc Natl Acad Sci, USA* 94: 6965-6970, 1997.
- Parnell SC, Magenheimer BS, Maser RL, et al.: The polycystic kidney disease-1 protein, polycystin-1, binds and activates heterotrimeric G-proteins *in vitro*. *Biochem Biophys Res Commun* 251: 625-631, 1998.
- DeAngelis CD, Rosenberg RN, Smith JM: Genomic medicine and the individual patient —Byte to bedside— A call for papers. *J Am Med Assoc* 284 (20): 22, 2000.

AUTOSOMAL DOMINANT POLYCYSTIC KIDNEY DISEASE

29. Somlo S, Ehrlich B: Human disease: Calcium signaling in polycystic kidney disease. *Curr Biol* 11: R356-R360, 2001.
30. Hanaoka K, Devuyst O, Schwiebert E, Wilson P, Guggino W: A role for CFTR in human autosomal dominant polycystic kidney disease. *Am J Physiol* 270: C389-C399, 1996.
31. González-Perrett S, Kim K, Ibarra C, et al.: Polycystin-2, the protein mutated in autosomal dominant polycystic kidney disease (ADPKD), is a Ca²⁺-permeable non-selective cation channel. *Proc Natl Acad Sci USA* 98: 1182-1187, 2001.
32. Vassilev PM, Guo L, Chen XZ, et al.: Polycystin-2 is a novel cation channel implicated in defective intracellular Ca²⁺ homeostasis in polycystic kidney disease. *Biochem Biophys Res Commun* 282 (1): 341-350, 2001.
33. Stayner C, Zhou J: Polycystin channels and kidney disease. *Trends Pharmacol Sci* 22 (11): 543-546, 2001.
34. Qian F, Watnick TJ, Onuchic LF, Germino GG: The molecular basis of focal cyst formation in human autosomal dominant polycystic kidney disease type 1. *Cell* 87: 979-987, 1996.
35. Loftus BJ, Kim U-J, Sneddon VP, et al.: Genome duplications and other features in 12 Mbp of DNA sequence from human chromosome 16p and 16q. *Genomics* 60: 295-308, 1999.
36. Rossetti S, Strmecki L, Gamble V, et al.: Mutation analysis of the entire *PKD1* gene: Genetic and diagnostic implications. *Am J Hum Genet* 68: 46-63, 2001.
37. Rossetti S, Chauveau D, Walker D, et al.: A complete mutation screen of the ADPKD genes by DHPLC. *Kidney Int* 61 (5): 1588-1599, 2002.
38. Phakdeekitcharoen B, Watnick T, Germino GG: Mutation analysis of the entire replicated portion of *PKD1* using genomic DNA samples. *J Am Soc Nephrol* 12: 955-963, 2001.
39. Geberth S, Ritz E, Zeier M, Stier E: Anticipation of age at renal death in autosomal dominant polycystic kidney disease (ADPKD)? *Nephrol Dial Transplant* 10: 1603-1606, 1995.
40. Milutinovic J, Rust PF, Fialkow PJ, et al.: Intrafamilial phenotypic expression of autosomal dominant polycystic kidney disease. *Am J Kidney Dis* 19: 465-472, 1992.
41. Boletta A, Qian F, Onuchic LF, et al.: Biochemical characterization of bona fide polycystin-1 in vitro and in vivo. *Am J Kidney Dis* 38 (6): 1421-1429, 2001.
42. Ponting CP, Hofmann K, Bork P: A latrophilin/CL-1-like GPS domain in polycystin-1. *Curr Biol* 9: R585-R588, 1999.
43. Grantham JJ: Pathogenesis of autosomal dominant polycystic kidney disease: recent developments. *Contrib Nephrol* 122: 1-9, 1997.
44. Germino G: Autosomal dominant polycystic kidney disease: a two-hit model. *Hosp Pract* 32: 81-102, 1997.
45. Yamaguchi T, Pelling J, Ramaswamy N, et al.: cAMP stimulates the *in vitro* proliferation of renal cyst epithelial cells by activating the extracellular signal-regulated kinase pathway. *Kidney Int* 57 (4): 1460-1471, 2000.
46. Sutters M, Yamaguchi T, Maser R, et al.: Polycystin-1 transforms the cAMP growth-responsive phenotype of M-1 cells. *Kid Int* 60: 484-494, 2001.
47. Hanaoka K, Guggino W: cAMP regulates cell proliferation and cyst formation in autosomal polycystic kidney disease cells. *J Am Soc Nephrol* 11: 1179-1187, 2000.
48. Marfella-Scivittaro C, Quinones A, Orellana SA: cAMP-dependent protein kinase and proliferation differ in normal and polycystic kidney epithelia. *Am J Physiol Cell Physiol* 282 (4): C693-707, 2002.
49. Sullivan LP, Wallace DP, Grantham JJ: Chloride and fluid secretion in polycystic kidney disease. *J Am Soc Nephrol* 9 (5): 903-916, 1998.
50. Gregoire J, Torres V, Holley K, Farrow G: Renal epithelial hyperplastic and neoplastic proliferation in autosomal dominant polycystic kidney disease. *Am J Kidney Dis* 9: 27-38, 1987.
51. Woo D: Apoptosis and loss of renal tissue in polycystic kidney diseases. *N Engl J Med* 333: 18-25, 1995.
52. Sujansky E, Kreutzer SB, Johnson AM, Lezotte DC, Schrier RW, Gabow PA: Attitudes of at-risk and affected individuals regarding presymptomatic testing for autosomal dominant polycystic kidney disease. *Am J Med Genet* 35 (4): 510-515, 1990.
53. Ravine D, Gibson RN, Walker RG, Sheffield LJ, Kincaid-Smith P, Danks DM: Evaluation of ultrasonographic diagnostic criteria for autosomal dominant polycystic kidney disease 1. *Lancet* 343: 824-827, 1994.
54. Nicolau C, Torra R, Badenas C, et al.: Autosomal dominant polycystic kidney disease types 1 and 2: assessment of US sensitivity for diagnosis. *Radiology* 213 (1): 273-276, 1999.
55. Torres VE, Wilson DM, Hattery RR, Segura JW: Renal stone disease in autosomal dominant polycystic kidney disease. *Am J Kidney Dis* 22: 513-519, 1993.
56. Torres V, Keith D, Offord K, Kon S, Wilson D: Renal ammonia in autosomal dominant polycystic kidney disease. *Kidney Int* 45 (6): 1745-1753, 1994.
57. Ecker T, Schrier RW: Hypertension in autosomal-dominant polycystic kidney disease: early occurrence and unique aspects. *J Am Soc Neph* 12 (1): 194-200, 2001.
58. Chapman AB, Johnson AM, Gabow PA: Pregnancy outcome and its relationship to progression of renal failure in autosomal dominant polycystic kidney disease. *J Am Soc Nephrol* 5 (5): 1178-1185, 1994.
59. Segura JW, King BF, Jowsey SG, Martin P, Zincke H: Chronic pain and its medical and surgical management in renal cystic diseases. In: Watson ML, Torres VE, eds. *Polycystic Kidney Disease*. Oxford: Oxford Medical Publications. p. 462-480, 1996.
60. Klahr S, Breyer J, Beck G, et al.: Dietary protein restriction, blood pressure control, and the progression of polycystic kidney disease modification of diet in renal disease study group. *J Am Soc Nephrol* 5 (12): 2037-2047, 1995.
61. Johnson A, Gabow P: Identification of patients with autosomal dominant polycystic kidney disease at highest risk for end-stage renal disease. *J Am Soc Nephrol* 8: 1560-1567, 1997.
62. Torres V: Polycystic liver disease. In: Watson MT, VE., ed. *Polycystic Kidney Disease*. Oxford: Oxford Medical Publications. p. 500-529, 1996.
63. Sherstha R, McKinley C, Russ P, et al.: Postmenopausal estrogen therapy selectively stimulates hepatic enlargement in women with autosomal dominant polycystic kidney disease. *Hepatology* 26 (5): 1282-1286, 1997.
64. Torres V, Rastogi S, King B, Stanson A, Gross J, Jr., Nagorney D: Hepatic venous outflow obstruction in autosomal dominant polycystic kidney disease. *J Am Soc Nephrol* 5: 1186-1192, 1994.
65. Telenti A, Torres V, Gross J, Jr, Van Scoy R, Brown M, Hattery R, Jr.: Hepatic cyst infection in autosomal dominant polycystic kidney disease. *Mayo Clin Proc* 65: 933-942, 1990.
66. Pirson Y, Chauveau D, Torres VE: Management of cerebral aneurysms in autosomal dominant polycystic kidney disease: unruptured asymptomatic intracranial aneurysms. *J Am Soc Nephrol* 13: 269-276, 2002.
67. Griffin MD, Torres VE, Grande JP, Kumar R: Vascular expression of polycystin. *J Am Soc Nephrol* 8: 616-626, 1997.
68. Torres VE, Cai Y, Chen X, et al.: Vascular expression of polycystin 2. *J Am Soc Nephrol* 12: 1-9, 2001.
69. International Polycystic Kidney Disease Consortium: Polycystic kidney disease: the complete structure of the *PKD1* gene and its protein. *Cell* 81: 289-298, 1995.
70. Inagawa T. Trends in incidence and case fatality rates of aneurysmal subarachnoid hemorrhage in Izumo City, Japan,

- between 1980-1989 and 1990-1998. *Stroke* 32 (7): 1499-1507, 2001.
71. Elzinga LW, Bennett WM: Miscellaneous renal and systemic complications of autosomal dominant polycystic kidney disease including infection. In: Watson ML, Torres VE, eds. *Polycystic Kidney Disease*. Oxford: Oxford Medical Publications. p. 483-499, 1996.
72. Ubara Y, Katori H, Tagami T, et al.: Transcatheter renal arterial embolization therapy on a patient with polycystic kidney disease on hemodialysis. *Am J Kidney Dis* 34 (5): 926-931, 1999.
73. Dunn MD, Portis AJ, Elbahnasy AM, et al.: Laparoscopic nephrectomy in patients with end-stage renal disease and autosomal dominant polycystic kidney disease (see comments). *Am J Kidney Dis* 35 (4): 720-725, 2000.
74. Qian Q, Harris PC, Torres VE: Treatment prospects for autosomal dominant polycystic kidney disease. *Kid Int* 59: 2005-2022, 2001.
75. Que F, Nagorney D, Gross J, Jr, Torres V: Liver resection and cyst fenestration in the treatment of severe polycystic liver disease. *Gastroenterology* 108: 487-494, 1995.