

## Pain management in polycystic kidney disease

ZAHID H. BAJWA, SANJAY GUPTA, CAROL A. WARFIELD, and THEODORE I. STEINMAN

*Department of Anesthesia and Neurology, Department of Anesthesia, and Renal Division, Department of Medicine, Beth Israel Deaconess Medical Center, Harvard Medical School, Boston, Massachusetts, USA*

**Pain management in polycystic kidney disease.** Pain is a common complaint in patients with autosomal-dominant polycystic kidney disease, and a systematic approach is needed to differentiate the etiology of the pain and define an approach to management. A thorough history is the best clue to the multifactorial causes of the pain, superimposed upon an understanding of the complex innervation network that supplies the kidneys. The appropriate use of diagnostic radiology (especially MRI) will assist in differentiating the mechanical low back pain caused by cyst enlargement, cyst rupture and cyst infection. Also, the increased incidence of uric acid nephrolithiasis as a factor in producing renal colic must be considered when evaluating acute pain in the population at risk. MRI is not a good technique to detect renal calculi, a frequent cause of pain in polycystic kidney disease. If stone disease is a possibility, then abdominal CT scan and/or ultrasound should be the method of radiologic investigation. Pain management is generally not approached in a systematic way in clinical practice because most physicians lack training in the principles of pain management. The first impulse to give narcotics for pain relief must be avoided. Since chronic pain cannot be “cured,” an approach must include techniques that allow the patient to adapt to chronic pain so as to limit interference with their life style. A detailed stepwise approach for acute and chronic pain strategies for the patient with autosomal dominant polycystic kidney disease is outlined.

Pain is a common complaint in patients with autosomal-dominant polycystic kidney disease (ADPKD), afflicting about 60% of patients with an established diagnosis [1]. The sensitivity of ultrasound to confirm a diagnosis of ADPKD in individuals who have a 50% a priori risk of having the disease by genetic linkage was studied by Ravine et al [2]. Currently used criteria of bilateral cysts with at least two in one kidney provides a sensitivity of 88.5% at age 15 to 29 years and 100% at 30 years of age and above. Less stringent criteria in subjects aged 15 to 29 years to establish a diagnosis of ADPKD for individu-

als at risk would be at least two renal cysts (unilateral or bilateral). More stringent criteria in those aged 30 to 59 years to establish a diagnosis is the presence of at least two cysts in each kidney. For at-risk individuals 60 years and older, at least four cysts in each kidney should be required. Other reviews of ADPKD have established less exact criteria to establish a diagnosis [3, 4]. Although there are other etiologies of polycystic kidney disease, including autosomal-recessive disease and acquired cystic kidney disease (generally associated with chronic failure) [5, 6], ADPKD is by far the most common and best studied of these cystic entities. Hence, ADPKD will be used as the prototype form of polycystic kidney disease throughout this review.

End-stage renal disease (ESRD) ultimately occurs in approximately 50% of patients with ADPKD by 60 years of age, and over the slow course of the disease there are a constellation of symptoms and associated findings. The spectrum of pain is the focus of this article. About 30% of ADPKD patients have accompanying polycystic liver disease upon presentation. However, the presence of liver cysts is age-dependent in ADPKD patients and may eventually be noted in up to 75 to 80% of these patients. Liver cysts are associated with various pain patterns (details below). Radiographic imaging techniques such as computed tomography (CT), ultrasound, and magnetic resonance imaging (MRI) are sensitive enough to detect cysts at a relatively early age and can help define which cysts are the largest and most amenable to approach [7].

Headache pain in the polycystic kidney disease population generates anxiety about the potential for a cerebral aneurysm. Detection varies between 0 and 40% of this patient group in multiple studies [8–10]. However, the realistic estimate is between 4 and 6% of the total ADPKD patient group. When a family history of cerebral aneurysms is noted, the incidence of aneurysms increases 18 to 26% [11]. Headache pain patterns will not be discussed further in this review, but it should be noted that in a survey of 184 patients with polycystic kidney disease conducted when we began to explore the issue of pain, the frequency of headaches is the same as in the general population. Chronic and migraine headaches are not re-

**Key words:** chronic pain, polycystic liver disease, diagnostic radiology, renal calculi, stone disease, computed tomography, magnetic resonance imaging, ADPKD.

Received for publication July 13, 2000  
and in revised form February 19, 2001  
Accepted for publication April 9, 2001

© 2001 by the International Society of Nephrology

lated to the presence of aneurysms. In 40 polycystic kidney disease patients with severe recurring headaches, none had a detectable cerebral aneurysm by magnetic resonance angiography (MRA).

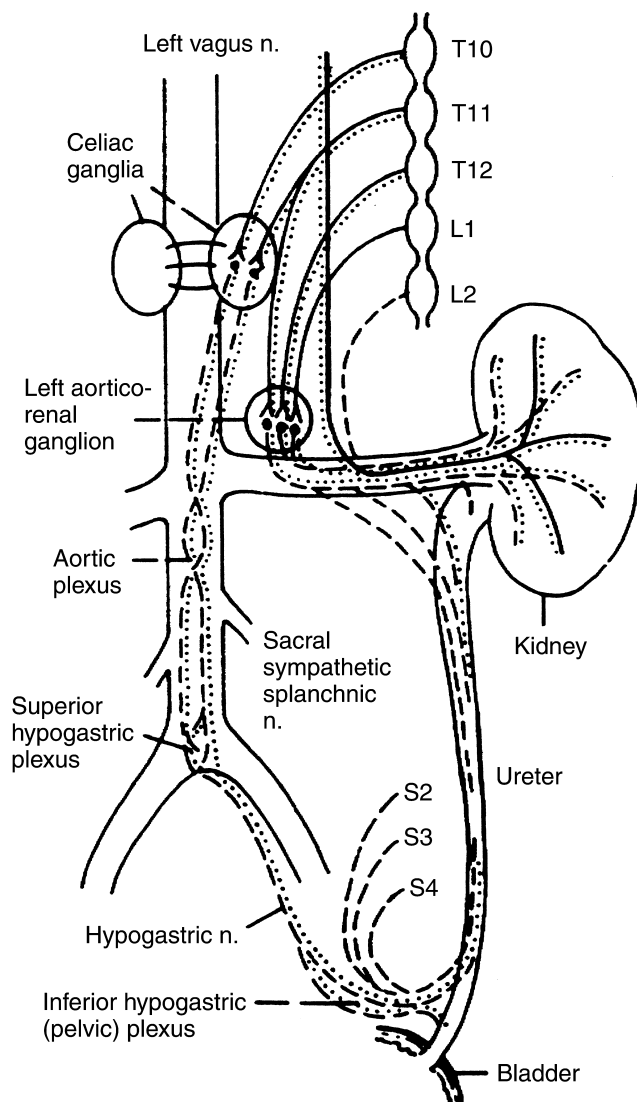
Hematuria related to cyst rupture, urinary tract infections (UTIs) and nephrolithiasis occur in many patients with ADPKD and the associated pain patterns are discussed in detail in this review. Severe persistent abdominal and flank pain affects patients afflicted with ADPKD [12, 13] and is a source of great frustration for those individuals because pain management is not well handled by many physicians. Segura et al outlined a detailed medical and surgical approach to chronic pain in renal cystic diseases [14], and this review is an update since their book chapter.

### SENSORY AND AUTONOMIC INNERVATION TO THE KIDNEYS

To discuss the pain associated with ADPKD, it is important to appreciate the diverse nerve supply to the kidneys. The kidneys and ureters are well supplied by sympathetic, parasympathetic and sensory afferent fibers (Fig. 1), and the renal sensory innervation is clearly associated with the perception of pain in the affected individuals. Schematic illustration of the autonomic and sensory nerve pathways supplying the kidneys and ureters in Figure 1 comes from the detailed work of Ansell, Gee, and Bonica [15].

The sympathetic supply of the kidneys comes from the aorticorenal and celiac ganglia as well as from the cephalad portion of the lumbar sympathetic trunk. The sympathetic nerves supplying the kidneys originate in spinal cord segments T10 to L1, traveling via the white rami communicantes to the paravertebral ganglia. From the 10th and 11th thoracic paravertebral ganglia, the sympathetic nerves travel via the lesser splanchnic nerves to synapse at the ipsilateral aorticorenal and celiac ganglia. From the 12th thoracic paravertebral ganglion, nerves travel via the least splanchnic nerve to synapse either in the aorticorenal ganglion or in the renal plexus. Also, the first lumbar splanchnic nerve synapses in the renal plexus. The post-ganglionic sympathetic nerves from the aorticorenal and celiac plexi also join the renal plexus. These nerves thus distribute to and innervate the vascular musculature and smooth muscles of the renal calyces and renal pelvis. They also extend along the afferent arterioles all the way to the juxtaglomerular apparatus.

The parasympathetic innervation of the kidneys originates from the vagus nerve. Most of these parasympathetic nerves traverse through the celiac plexus to the renal plexus; some bypass the celiac plexus and pass directly to the renal plexus. Via the renal plexus, the preganglionic parasympathetics travel to the smooth muscles of the renal pelvis where they synapse with the



**Fig. 1. Sympathetic, parasympathetic and sensory innervation supplying the kidney.** The solid line (—) represents the sympathetic component. The dotted line (····) reflects the parasympathetic nerve supply. Afferent (sensory) fibers are represented by the dashed line (---) and travel with the autonomic nerves. See text for details. (Reproduced with permission from Lippincott, Williams and Wilkins [14].)

short post-ganglionic fibers. The parasympathetics supply the muscles in the renal pelvis and calyces, but not the parenchyma of the kidneys.

Sensory innervation of the kidneys comes from the 10th through 12th thoracic spinal nerves, which pass through the thoracic sympathetic ganglia, and travel via the splanchnic nerves to the renal plexus and then to the kidneys. Afferent sensory fibers traveling with the vagus nerve may explain the nausea that sometimes accompanies pain. Perception of renal pain is mainly in unmyelinated C-fibers, while the pelvis and calyces are innervated by thinly myelinated (A-delta) fibers from the kidney, coursing through the periarterial nerves [16, 17].

Interestingly, it was found on the feline model that 95% of the spinal cord dorsal horn neurons that were activated by renal sensory afferents also had receptive fields on the skin in the appropriate dermatomes [18]. There is also extensive cross connection with innervation to other visceral structures, suggesting that renal pain can manifest either in a localized or referred pattern. For example, stimulation of the kidney at the renal pelvis produces pain at the costovertebral angle ipsilaterally and also can frequently be referred to the ipsilateral testicle or ovary.

### ACUTE PAIN IN ADPKD

Pain in patients with polycystic kidney disease can be both acute and chronic, often being difficult to manage in patients with more severe symptoms. However, with the utilization of a variety of traditional and recently available pain management techniques, pain can be managed effectively in most of these patients. In addition, patients can be taught “how to live with their pain” since permanent cure of chronic pain is often not a realistic goal. Behavioral modification approaches can help patients adapt to chronic pain so as to not interfere with their lifestyle. ADPKD patients may suffer complications such as infected cysts, cyst rupture/hemorrhage, and nephrolithiasis that often cause crippling acute renal pain. Discussed below are the most common etiologies of acute pain.

#### Infection

Infected cysts can cause diffuse pain that may be unilateral or bilateral, and the pain pattern can be similar to pyelonephritis in patients with noncystic kidneys. UTIs in patients with ADPKD, however, can be much more difficult to diagnose and manage than in patients with non-cystic kidneys. UTIs occur in many patients with ADPKD and, as expected, the incidence is much higher in women than in men. In one report, 68% of women with ADPKD had UTIs as compared with only 19% of men [19]. Both hematogenous spread and ascending infection are the presumed causes for cyst involvement. A sudden increase in flank pain associated with fever is the most common presentation of cyst infection. The pain pattern tends to stay in one general area without radiation, not being relieved by position change. Infected cysts may not be in communication with the draining urinary tract in patients with ADPKD and hence the urinalysis may be relatively benign and the urine cultures can be persistently negative [20].

Management of upper tract infections in ADPKD may be difficult, since antibiotics may not be able to cross the epithelial lining of the cysts and produce a high enough concentration in the cyst fluid. Highly ionized water-soluble drugs may have a low ability to penetrate this barrier, whereas the use of nonionized lipid soluble anti-

biotics generally can improve delivery into the cyst [21]. Therefore, many antibiotics such as the penicillins, cephalosporins, and aminoglycosides that have traditionally been first line therapy for severe UTIs may not be effective in ADPKD. Drugs with good cyst-penetrating ability, such as clindamycin, trimethoprim-sulfamethoxazole, metronidazole, and fluoroquinolones may be more effective. However, it is possible that even these may not be effective, necessitating surgical drainage of the infected cysts. It is imperative that these UTIs be promptly treated to prevent ongoing pain and other complications in these noncommunicating infected cysts such as sepsis, perinephric abscess, and subsequent renal failure [22, 23].

#### Hemorrhage

Another common cause of acute flank pain in association with gross hematuria in ADPKD is the rupture of cysts. Hemorrhage may be into a communicating urinary tract [24]. However, it is not certain that gross hematuria represents hemorrhage into cysts communicating with the urinary tract, since most cysts derived from proximal and distal tubule segments grow as a result of aberrant tubulogenesis, and become walled off and separate from the tubules of origin by the time they become detectable by imaging studies [25]. Gross hematuria is present in as many as 43% to greater than 50% of the patients with polycystic kidney disease [26]. Hemorrhage into a cyst occurs without gross hematuria when there is no communication with the urinary tract. The frequency of hematuria from cyst rupture correlates directly with the size of the kidneys, the incidence of hematuria increasing dramatically when one or both of the kidneys is larger than 15 cm [27]. Also, hypertensive ADPKD subjects are more likely to have gross hematuria than normotensive patients. Prognostic characteristics are noted with gross hematuria; the greater the number of episodes, the worse the prognosis. Increased episodes of gross hematuria are noted in association with a higher baseline serum creatinine and episodes of bleeding before age 30 carry a worse renal outcome [28].

In general, the episodes of hematuria are usually self-limited, lasting two to seven days. These episodes tend to resolve spontaneously with conservative management consisting of bedrest and hydration, but persistent bleeding has been noted to occur for weeks. Pain related to cyst rupture tends to be localized and definable by finger point. However, referred pain to another location in the abdomen or up to the shoulder (for example, with right kidney cyst rupture simulating biliary colic) can occur with hemorrhage into a larger cyst, resulting in compression of surrounding structures.

It is possible for significant bleeding into the renal cysts to occur with subsequent formation of clots. This in turn may lead to urinary tract obstruction and severe renal colic. Prolonged bed rest, intravenous hydration,

heat and judicious narcotic administration are often necessary in this circumstance.

It is also possible for cysts on the surface of the kidneys to rupture and subsequent hemorrhage can result in a subcapsular hematoma. The patient may then experience a mild steady flank pain until the hematoma has been reabsorbed. Although nonsteroidal anti-inflammatory drugs (NSAIDs) may be very helpful in the case of colicky pain, they must be used cautiously and should not be the first line of treatment (see section on **Systemic Analgesics**). Hematuria may rarely be so severe and/or persistent as to necessitate transfusion. In these cases, either nephrectomy or renal arterial embolization may be necessary to control the bleeding. Embolization, although less invasive than nephrectomy, can in itself cause severe continuous pain associated with abdominal distension. This pain is due to renal parenchymal ischemia in an enlarged kidney following embolization, and can be difficult to control with conservative management and non-opioid pharmacologic intervention. Even with high doses of systemic opioids, the pain control can often be inadequate. However, a combination of epidural anesthesia and analgesia, using a mixture of local anesthetic and opioids during the procedure, and for several days thereafter, may be an excellent way of controlling such severe pain (see section on **Sequential Approach to Pain Management**) [29].

### **Nephrolithiasis**

Renal colic caused by kidney stones, another complication of ADPKD, occurs in about 20% of patients with ADPKD [30]. When considering the spectrum of both symptomatic and asymptomatic stones, about a third of the ADPKD patients have nephrolithiasis. This much higher incidence of nephrolithiasis than in the general population is a cause of significant morbidity in ADPKD patients because of flank pain, hematuria and urinary tract infection. The prevalence of renal calcifications, which represent stones within the collecting system, interstitial calcifications, or calcifications within cysts, was found to be 50% by CT in a study by Levine and Grantham [31]. While patients with ADPKD develop a variety of kidney stones (calcium oxalate, calcium phosphate, calcium carbonate, struvite), uric acid stones are more common in polycystic kidney disease patients as compared to the incidence in the general population, accounting for up to 50% of the calculi formed [32, 33]. Mechanisms responsible for the increased association between ADPKD and nephrolithiasis remain conjecture. Patients with ADPKD may be predisposed to stone formation either because of a metabolic defect, structural abnormality secondary to cyst growth, renal tubular stasis, or a combination of these factors. It is noted that approximately 50% of ADPKD patients have hypocitraturia (abstract; Fan et al, *J Urol* 155:643A, 1996). There is

no difference in other normal value urinary parameters, including urinary oxalate, between ADPKD stone formers and non-stone formers.

Renal function of adult ADPKD patients with kidney stones is significantly worse than in patients without stones. ADPKD stone formers have larger predominant cyst size compared to non-stone formers. Increased cyst number also is associated with stone formation (abstract; Glass et al, *J Urol* 155:643A, 1996). Therefore, anatomic deformity related to cyst number, size, and growth may contribute to the formation of kidney stones, possibly through a mechanism of increased urinary stasis [34]. Because of the compressed and distorted renal calices, treatment modalities such as ureteroscopy, extracorporeal shock wave lithotripsy (ESWL), and nephrolithotomy are more difficult in patients with ADPKD [35–38]. Since these therapeutic and palliative procedures may not be as efficacious, ADPKD patients may have to endure prolonged and repeated episodes of renal colic while undergoing medical management addressed towards the etiology of the stone formation. A rapidly progressive distension produced by stone movement usually causes a much more severe pain than a slowly increasing distension. Thus, it is critical that pain control be adequately addressed while a detailed evaluation is underway.

Renal prostaglandins may be a major contributing factor in the symptom complex known as renal colic. Acute ureteral obstruction by a stone can increase renal pressure, leading to a release of inflammatory mediating renal prostaglandins [39]. These prostaglandins, especially prostaglandin E<sub>2</sub> (PGE<sub>2</sub>), cause vasodilation of the afferent arterioles in the kidney and inhibition of antidiuretic hormone (ADH), with a resultant diuresis and a further increase in renal pressure. Thus, a vicious cycle may be established [40]. In the rabbit, prostaglandins also can increase the contractile movement in the smooth muscle of the renal pelvis while promoting edema and inflammation in the smooth muscle of the affected areas [41].

Prostaglandin synthesis inhibitors, such as NSAIDs, would seem to be the obvious logical choice in combating pain from kidney stones. NSAIDs' administration leads to an immediate reduction in smooth muscle movement in the ureter as well as to a decrease in diuresis by counteracting the PGE<sub>2</sub> effects on inhibiting ADH [42]. NSAIDs will decrease inflammation and edema, allowing stone passage down the ureter. Studies comparing the efficacy of NSAIDs, especially indomethacin versus opioid analgesic preparations, in relieving renal colic have shown that NSAIDs are as effective, if not more so, in providing pain relief for this situation. Hetherington and Philip reported a 93% satisfactory pain relief from renal colic with intramuscular diclofenac [43]. Another study showed that a single dose of 10 mg of parenteral ketorolac was as efficacious as 100 mg of intramuscular meperidine in this setting [44].



Non-steroidal anti-inflammatory drugs must be used judiciously, avoiding prolonged use in patients who have renal compromise secondary to ADPKD. Short-term use seems reasonable, limiting the NSAID administration to no more than two to three days. Even healthy people with intact renal function have reported acute flank pain and renal dysfunction associated with use of NSAIDs [45].

It is yet unproven that cyclooxygenase-2 (COX-2) inhibitors may be more renoprotective. Since it is stated that COX-2 inhibitors will not interfere with renal PGE synthesis, they supposedly will not inhibit the vasodilatory and ADH effects of PGE<sub>2</sub>. However, COX-2 is constitutively expressed in the kidney and is up-regulated during sodium restriction. Therefore, these agents to some extent interfere with renal prostaglandin synthesis (see section on **Systemic Analgesics** for a detailed discussion on COX-2 inhibitors).

Opioids are still the cornerstone of analgesic therapy for acute renal colic, even though they do not influence renal prostaglandins or renal pelvic pressure. An increase in the tonicity of smooth muscle occurs with opioids and subsequent ureteral spasm during colic is not desirable. Also, the possible buildup of active and potentially toxic metabolites of certain opioids, such as normeperidine, need to be considered in patients with renal failure who may receive Demerol® for as short as three to four days. Even after stopping this opioid, a near coma-like state can persist for days.

## **CHRONIC PAIN IN ADPKD**

### **Mechanical back pain in ADPKD**

Chronic back pain is a common and frustrating problem in this population. Enlarging cysts can cause increased abdominal girth, leading to increased lumbar lordosis that accelerates degenerative changes in the spine. This “imbalance” of the spine can be the source of a variety of different pain syndromes. The mechanical form of back pain tends to get worse with passage of time. A personal observation made during an ADPKD Cohort Study to determine the volume of kidney cysts via MRI demonstrated hypertrophy of the lumbodorsal muscle group. Ten patients with ADPKD had an average lumbodorsal muscle thickness at the L4-S1 level of 38.7 mm. In contrast, ten age- and gender-matched non-ADPKD patients, who had undergone an abdominal MRI for a variety of reasons, had a 31.3 mm thickness of this muscle group measured at the same level. The ADPKD patients were known to have the disease at least ten years, and all, except for one, had a serum creatinine equal to or less than 1.4 mg/dL at the time of study. A more detailed study now will be conducted to see if this preliminary observation of an average 7.4 mm difference on lumbodorsal muscle group hypertrophy is a reproducible finding. There will be a need to document our preliminary

observation that the greatest degree of hypertrophy occurs in patients who have the largest kidney cyst volume. Therefore, muscle enlargement could be the basis of the “imbalance” and the major cause for chronic low back pain in this population. This slow process contrasts to the pain pattern related directly to cyst formation/compression. As in the general population, the problem of back pain is complex and requires a thorough evaluation to ascertain the exact cause. If MRI demonstrates lumbodorsal muscle hypertrophy, then the focus should be on treating mechanical back pain. For diffuse low back pain, physical therapy techniques and trigger-point injections using either local anesthetics alone or in combination with steroids can be helpful. Also, a combination of physical therapy and transcutaneous electrical nerve stimulation (TENS) unit use can be an adjunctive maneuver [46].

Since bilateral cyst enlargement can be asymmetric, the pelvic shift in posture tends to produce low back pain localized to one side more than the other. This chronic alteration in posture appears to accelerate the development of disc disease in the lumbosacral region. When polycystic liver disease compounds the picture, the postural changes become more pronounced and subsequent back pain can be a debilitating complication. Therefore, an MRI may demonstrate disc disease with or without muscle hypertrophy, and this radiologic study becomes an essential tool in assessing back pain in this population.

For ADPKD patients with spinal stenosis or lumbosacral radiculopathy due to disc disease or degenerative spine disease, epidural steroid injections are often helpful [47, 48]. These injections also can be performed for thoracic or cervical radiculopathy that results from disc disease or degenerative changes of the spine. Facet blocks can have diagnostic and therapeutic value if facet arthritis is the source of pain. Pain arising from the sacroiliac joint is frequently under-diagnosed and seems to be a common source of pathology in patients with polycystic kidney disease. Injections using a combination of local anesthetics and steroids as well as physical therapy techniques can alleviate pain.

### **Chronic pain related to cyst formation**

Pain can occur due to compression of cysts on the surrounding tissues, traction on the pedicle of the kidney, and distension of the renal capsule. The pain severity generally correlates with the size of the kidneys, but there are some marked exceptions. Some patients with relatively small cysts, less than 3 cm, can have severe pain while others with very large cysts do not experience much discomfort. The reason for this variation is not clear. Pain related directly to cyst formation tends to be a steady nagging discomfort, with the standing position and walking exacerbating the discomfort. Patients can frequently localize the source of pain with one finger, anterior abdominal being more common than localized

back pain. However, the pinpoint pain does not readily correlate with the largest sized cysts noted on radiological imaging (ultrasound, CT scan, MRI).

With massive cyst formation early satiety can occur due to compression of the greater curvature of the stomach and /or duodenal loop, (the two most common gastrointestinal abnormalities noted on CT scan with contrast). Pain related to enlarging cysts does not correlate with the level of renal function. Severe discomfort is noted at all levels of kidney function; when pain is the predominant complaint it begins early in the course of demonstrable cyst formation. A detailed history focusing pain location, duration, associated symptoms and maneuvers to produce relief will frequently delineate pain related directly to cyst formation versus mechanical back pain due to a change in posture from enlarging cysts.

Polycystic liver disease in the patient with ADPKD can cause the most disabling pain pattern, often more severe than that related to kidney cysts. Multiparous females appear to be the most affected group. Cysts can become so massive as to occupy most of the abdominal cavity and produce intractable pain/discomfort that is resistant to every modality of therapy. Pain/discomfort tends to be most severe when the patient is erect. Early satiety is noted frequently for the same reasons as above due to polycystic kidneys, but this complaint occurs more frequently with liver cysts than with renal cysts. Management approaches to pain are discussed below in detail, outlining a stepwise treatment plan.

### Sequential approach to pain management

All the approaches discussed below refer to general principles for pain control and are not specific for ADPKD or chronic renal failure. However, our team has used these modalities to address pain problems in our ADPKD population. Several of the principles result from animal experimentation and other principles are derived from clinical investigation in patients with chronic pain of various etiologies.

A concept that must be employed in patients suffering from chronic pain is not to set expectations too high. If the patient is led to believe that permanent cure of chronic pain will result from the planned intervention, then disappointment and frustration will frequently occur. A dissatisfied patient will lead to a scenario of doctor shopping and an expectant long list of both non-narcotic and narcotic analgesics constantly being consumed by the disgruntled patient. The most important first step by the physician is to non-judgmentally listen to the patient, then validate the significance of their pain suffering. Since pain cannot be directly measured, an expression of understanding of their situation is a major part of the therapeutic intervention. Verification of their symptom complex makes it easier for the patient to proceed with a planned sequential approach to pain management, even

when the initial step(s) of intervention do not bring desired results. Repeatedly, it must be emphasized that the goal of treatment is to have the patient adapt to their pain, since cure of chronic pain is infrequent. Reduction of interference with a desired lifestyle should be an expressed tenet of treatment. This generalized approach fits into the framework of psychobehavioral modification and should be an integral part of any chronic pain treatment program.

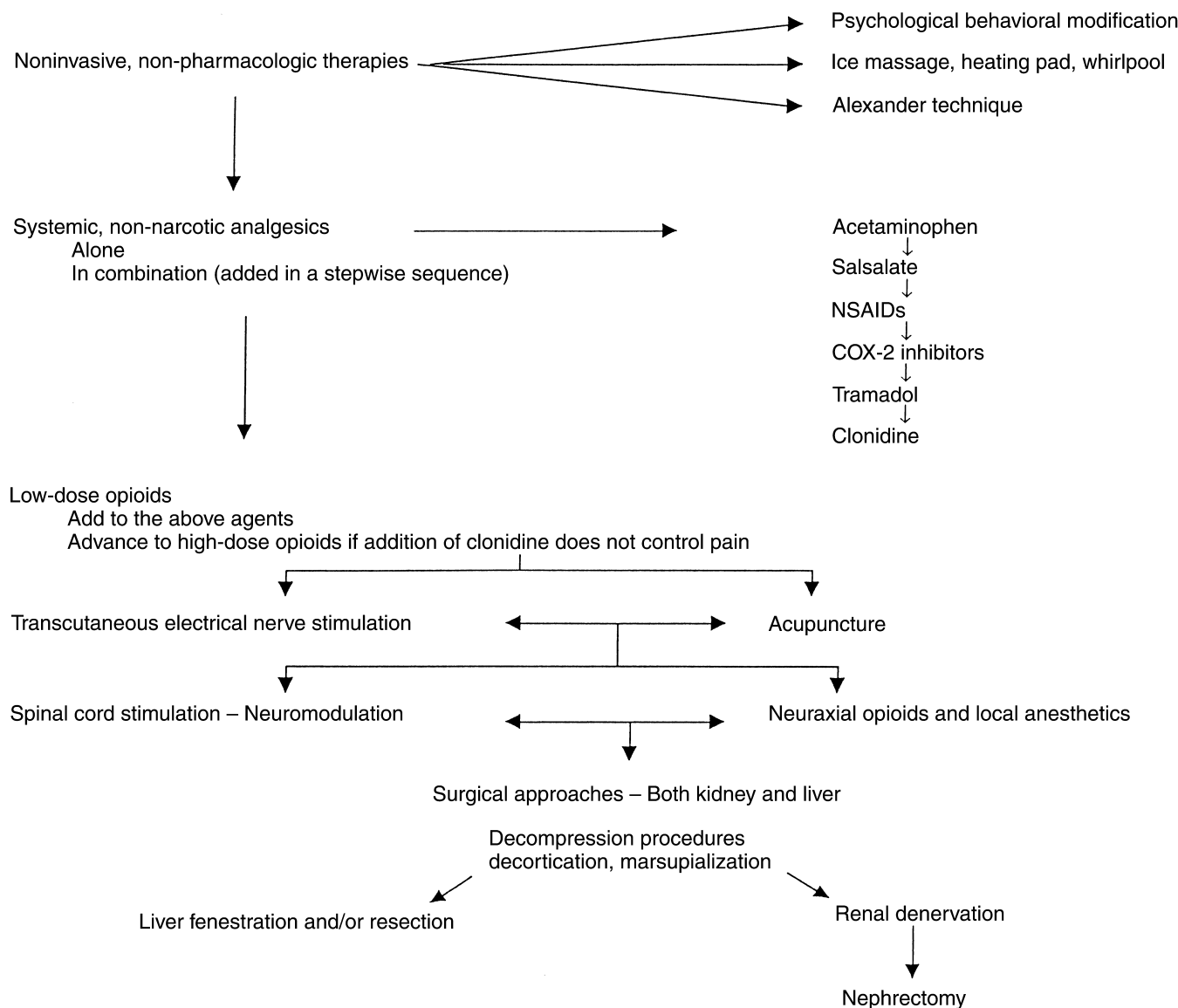
The various options for an effective combined and sequential chronic pain management in ADPKD are noted in Figure 2. They can be summarized as follows: (1) physical measures (ice massage, heating pads, whirlpool, Alexander technique); (2) psychobehavioral modification techniques; (3) systemic analgesics; and (4) physical interventions such as (in sequential order), (a) TENS, (b) acupuncture, (c) autonomic plexus blockade, (d) neuromodulation by spinal cord stimulation, (e) neuraxial opioids and local anesthetics, (f) surgical decompression of kidney and liver cysts, and (g) hepatectomy (partial) and/or nephrectomy.

The severity of pain varies from patient to patient and a combination of the above modalities may be most useful. Management of pain should initially be conservative, employing non-narcotic analgesics and other non-invasive therapies. A sequential approach to pain management is advised as in Figure 2 and detailed below.

### NON-PHARMACOLOGIC THERAPY/ PHYSICAL MEASURES

An initial attempt to control mild-to-moderate pain should be with simple adjuvants such as heating pads or ice massage, even before trying non-narcotic analgesics. Ice massage and heating may help decrease acute intermittent spasms, especially if muscle spasm is related to the pain. If the pain is due to enlarged cysts tugging on the renal pedicles, supporting garments or corsets may benefit the patient.

The Alexander technique (AT) is a non-exercise approach to the improvement of body mechanics that involves a slow, long-term learning process [49–51]. Physical manipulation while clothed is followed by learning how to hold and move your body in a correct anatomical position. After many sessions with a certified AT teacher, body positioning becomes “natural” and many musculoskeletal complaints are eliminated or markedly reduced [52]. In addition, the AT has been shown to reduce depression and improve the management of disability in a cohort of patients with Parkinson’s disease [53]. There have been no controlled studies performed in ADPKD patients with refractory pain, but personal observation in isolated cases indicates that AT should be part of the therapeutic armamentarium for pain relief. Whirlpool treatments can be employed in conjunction with massage therapy to enhance results with the AT.



**Fig. 2. Pain management in polycystic kidney disease patients should follow a sequential approach, starting with measures that are noninvasive, simple and have relatively few side effects, and then slowly progress towards more complex and invasive measures.** The first step is to set expectations that pain may not be “cured,” but there will be adaptations that will allow the patient to adjust to the chronic pain. Combining different modalities may be needed for refractory pain.

**SYSTEMIC ANALGESICS**

**Acetaminophen**

We recommend a step-ladder approach for the pharmacologic therapy of pain, starting with the least potentially toxic agents and using higher sequential doses than usual before adding other drugs. Our suggestion would be to start with acetaminophen. It is effective in the treatment of mild to moderate pain and is devoid of any significant gastrointestinal side effects such as those associated with aspirin and other NSAIDs. This low incidence of gastrointestinal side effects makes acetaminophen particularly useful in elderly. Acetaminophen is recom-

mended by the National Kidney Foundation as the first analgesic of choice for patients with preexisting renal disease and can be started at a dose of 500 to 650 mg orally every six hours as required for pain relief [54]. The dose can be increased to 1000 mg every four to six hours. There is a need to be aware that a clinically important adverse event occurring with chronic acetaminophen use can be prolongation of the half-life of warfarin [55]. While therapeutic doses of acetaminophen rarely are associated with hepatic toxicity, caution must be taken not to exceed 4000 mg per day since acetaminophen has been associated with hepatotoxicity at high doses in patients with existing liver disease. This drug

should be avoided in patients with chronic alcohol abuse since hepatic toxicity has been reported in this scenario [56–58]. If a patient consumes three or more alcohol-containing drinks per day, clinicians should attempt to reduce this consumption before recommending chronic use of any analgesic, including acetaminophen. With regards to ADPKD, there is no evidence in the literature that acetaminophen has kidney or liver toxicity (even in patients with extensive polycystic liver disease) that is different from other disorders causing chronic renal failure.

### NSAIDs

Non-steroidal anti-inflammatories (NSAIDs) are used frequently by clinicians as first-line agents to control pain, but therapy should be limited to several days in patients with renal insufficiency because of the noted toxicity profile. Antiplatelet action of NSAIDs may be detrimental in the setting of hematuria. Also, renal function may already be impaired despite a serum creatinine in the “normal” range and careful monitoring of kidney function is necessary when NSAIDs are used even for brief periods. Agents currently available inhibit both cyclooxygenase type I (COX-1) and II (COX-2). Cyclooxygenase is required for the synthesis of prostaglandins and thromboxanes, and inhibition leads to blockage of PG formation in inflamed tissues (via COX-2), as well as blocking prostaglandins in tissues like the stomach and kidney (via COX-1). COX-1 is expressed constitutively in most tissues and is thought to play a major role in protecting the gastric mucous [59]. Therefore, inhibition of COX-1 by NSAIDs, and the resultant blockage of PG formation, is associated with renal toxicity and gastric ulceration [60, 61]. Catastrophic gastrointestinal events in elderly patients taking NSAIDs occur in a dose-dependent manner [62]. Risk factors for reversible renal failure in patients with intrinsic renal disease who are treated with NSAIDs include age 65 or older, hypertension, congestive heart failure, and concomitant use of diuretics and/or angiotensin-converting enzyme inhibitors [63, 64]. Given the above side effects, NSAIDs are not suitable for long-term use.

### COX-2 inhibitors

The recently developed COX-2 inhibitors have a high degree of selectivity for the inducible form of cyclooxygenase (COX-2) over the constitutive form (COX-1) and are claimed to be associated with less gastric and renal side effects [65–67]. While these drugs are comparable to NSAIDs for reducing pain, they do not interfere with platelet aggregation. Hence, fewer endoscopically detected gastric and duodenal ulcers have been reported when compared to traditional NSAIDs. However, targeted disruption of the COX-2 allele in mice has resulted in severe renal problems, supporting the clinical observation that COX-2 inhibitors can cause renal toxicity. In

elderly patients receiving a low salt diet, the effects of COX-2 inhibition on decreasing glomerular filtration rate (GFR) are similar to those observed with non-selective NSAIDs [68]. Therefore, this newest class of analgesics must be used with caution in patients with mild to moderate renal insufficiency and avoided in face of severe impairment of kidney function (GFR <25 cc/min).

Potential drug interactions between COX-2 inhibitors and angiotensin-converting enzyme inhibitors (ACEI), warfarin and methotrexate exist [69]. COX-2 inhibitors may reduce the antihypertensive effect of ACEI, increase the effects of warfarin and increase methotrexate levels. It has been postulated that COX-2 inhibitors may bind tumor necrosis factor (TNF), a protein associated with joint pain and inflammation [70]. Since TNF is part of the internal response to infections, the theoretical possibility is raised that polycystic kidney disease patients with serious infections or sepsis could possibly experience severe complications if maintained on these agents. However, there is no clinical evidence to date to support such a relationship between COX-2 inhibitors and infection. If COX-2 inhibitors are used, the dosage ranges between 100 to 200 mg bid for Celecoxib (12.5 to 50 mg qd b.i.d. for Rofecoxib). As with NSAIDs, short-term use is recommended until a complete clinical profile on this class of compounds is established. Considering the potential toxicity, a better choice for pain control, after acetaminophen, may be the non-acetylated salicylates, such as salsalate. Only after failure of relief with acetaminophen and then salsalate should NSAIDs and COX-2 inhibitors be tried for a short term.

## ADJUNCTIVE NON-NARCOTIC AGENTS

### Tramadol

Tramadol (Ultram®) is a centrally acting non-NSAID analgesic with a dual mechanism of action, indicated for moderate to moderately severe pain. It is a mu opioid receptor agonist (binding affinity 6000 times less than morphine) that also inhibits norepinephrine and serotonin re-uptake by the nerve cells. The side effects include nausea, somnolence, constipation, and vomiting. Abuse potential in several European trials is claimed to be lower than with other narcotics. Tramadol does not inhibit prostaglandin production and so it lacks any gastrointestinal and renal prostaglandin-inhibiting side effects. In cases of moderate to severe pain, 50 to 100 mg of Tramadol may be given every four to six hours. Patients on this analgesic while also taking Serotonin selective re-uptake inhibitor (SSRI) antidepressants can develop a serotonin syndrome, since Tramadol can also inhibit the re-uptake of serotonin and norepinephrine [71]. This reaction, characterized by nausea, diaphoresis, muscle weakness, tremor and confusion, can occur within a few days of taking both medications. Tramadol can be tried alone for analgesia, but it fre-



quently can be effective as an adjunctive agent to another non-narcotic or narcotic agent.

### Clonidine

Anesthesiologists have long used clonidine as a sole or adjunctive agent for pain control. Analgesia is produced by the action of clonidine on stimulating the  $\alpha_2$ -adrenoceptors. Stimulation of the  $\alpha_2$ -adrenoceptors reduces sympathetic outflow from the central nervous system, a factor in pain control. Pain control is achieved from systemic, epidural or intrathecal administration of clonidine. However, clonidine is more potent after neuraxial administration in contrast to systemic administration, indicating a spinal site of action [72]. With epidural clonidine administration there is a strong correlation between clonidine concentration in the cerebrospinal fluid and analgesia [73]. For the ADPKD patient, clonidine is recommended as an adjunctive agent, especially adding it to local anesthetics for epidural, spinal or peripheral blockade since it prolongs and intensifies anesthesia. When epidural clonidine is used with opiates, the combination offers the advantage of reduced dose of each component (with correspondingly fewer side effects). Clonidine, both in oral and transdermal patch forms, can be a useful adjuvant for control of moderate to severe pain, especially if patients are requiring a large amount of opioid medications.

Clonidine produces dose-dependent side effects of hypotension, bradycardia and sedation, and patients need to be warned about the consequences of such. In addition, the concomitant use of tricyclic anti-depressants (sometimes also used for adjunctive pain relief) may accentuate the side-effect profile, but the hypotensive effects of clonidine may be reduced by combination use.

### Opioids

Opioids remain the mainstay of pain management for moderate to severe pain, especially if the pain is not controlled by above non-opioid agents. The main concerns about the use of opioids are their side effects: nausea, vomiting, constipation, sedation and the potential for abuse. Also, if there is associated renal dysfunction, dose adjustment to less frequent intervals is necessary since excretion of these drugs may be prolonged. For the purpose of chronic non-malignant pain control, opioids are usually administered orally or transdermally. Both short acting and long acting preparations (12 to 24 hours) are available for oral use. Fentanyl patches are available for transdermal use and can be very effective. Each patch provides analgesia for three days and the dosage starts at 25  $\mu\text{g}/\text{h}$ .

The most effective analgesia may be obtained by using a combination of opioid and other drugs. The delivery of different classes of analgesics results in effective pain relief by synergistic or additive effects with a reduced

incidence of side effects because of lowered doses of each agent. Acetaminophen, salicylates, NSAIDs, COX-2 inhibitors, tramadol, or clonidine can be combined with opioids as long as there is an awareness of potential major side effects. Systematic pharmacologic intervention needs to start with one drug and then follow a sequence of stepwise additions as needed for chronic pain management in ADPKD patients.

## PHYSICAL INTERVENTIONS

### Transcutaneous electrical nerve stimulation

Transcutaneous electrical nerve stimulation (TENS) unit application can be a useful adjunct [46, 74, 75], especially if used as part of a stepwise sequence for pain control. In the cat, almost 95% of the dorsal horn cells with renal input may get concomitant somatic receptive field input. Nam et al showed that TENS electrodes placed on the somatic receptive fields of these neurons on the skin reduced their responsiveness to nociceptive stimuli [18]. TENS decreased the dorsal horn cell responsiveness to C-fiber direct electrical stimulation to about 39% of control. Also, the dorsal horn cell responsiveness to ureteral occlusion was decreased to 38% of control. Finally, with renal artery occlusion, the dorsal horn cells were only 46% as responsive with TENS use as compared to controls. These analgesic effects lasted from 10 to 15 minutes after the TENS unit was turned off. We have found that intermittent use of a TENS unit can often help control chronic pain, especially in patients with chronic dull aching pain. A trial can be given for two weeks, and if found effective it can be used long term with virtually no side effects.

### Acupuncture

Another useful adjunct can be acupuncture treatment. Acupuncture and electrical stimulation of acupuncture points are minimally invasive and avoid the side effects of analgesics. Pain relief with acupuncture occurs via activation of the gate-control system in which large nerve fibers are stimulated and suppress small fibers that transmit signals in the dorsal horn of the spinal cord [76, 77] or through release of neurochemicals in the central nervous system [78–80]. Lein et al showed that electrical stimulation at various auricular, somatic, and combination group acupuncture points produced a significant elevation in pain threshold [46]. Yao reported that in the rabbit model, electroacupuncture to the hind leg produced partial inhibition of the splanchnic nerve activity while increasing the inhibition of renal nerve activity caused by stimulation of the brain osmoreceptors with hypertonic saline [75]. These examples and others show that further investigation into acupuncture may be warranted as part of chronic pain management in patients with ADPKD.

### Autonomic plexus blockade

As discussed before, the autonomic nervous supply to kidney, both sympathetic and parasympathetic, relay via the celiac plexus. Celiac plexus block is commonly used for relief of cancer pain from various abdominal viscera [81]. An increasing number of pain specialists are now using celiac plexus blocks for chronic nonmalignant pain [82–84] and it could prove to be of significant benefit in reducing pain in ADPKD patients. These blocks are usually first done with local anesthetic agents, with or without steroids, under fluoroscopic guidance. If relief is obtained using local anesthetics, longer lasting results may be obtained with the use of neurolytic blocks using alcohol or phenol [85]. Patients with moderate to severe pain would be good candidates for a celiac plexus block trial. Neurolytic blocks may last anywhere from six months to a year.

### MAJOR INVASIVE PROCEDURES

#### Spinal cord stimulation

Neuromodulation of the spinal column by implanting electrodes in the epidural space is another method being increasingly employed for chronic pain control. This is an invasive procedure and requires a long-term implantation of a device. The principle of action is probably similar to TENS, but has the additional benefit of more central intense effects and is also devoid of the cutaneous discomfort associated with a TENS unit. Before a permanent stimulator is implanted, a trial stimulator electrode is used for a few days to assess the beneficial effects. In a selected group of patients, spinal cord stimulation (SCS) can be an excellent choice for pain control. Since it is an implanted device, it is important that the patient make a well-informed decision about the implantation. For moderate to severe pain it can be a very useful non-pharmacologic way of providing partial to complete relief and can be used as an effective adjuvant [86, 87]. Research studies also suggest that SCS increases the local visceral blood flow and may help reduce pain related to ischemia.

#### Neuraxial opioids and local anesthetics

If the pain is moderate to severe, opioids can be given via the epidural or intrathecal route [88, 89]. The amount of opioids given by this route is significantly less (especially when given in conjunction with local anesthetics), and thus the systemic side effects of opioids are reduced. This route of administration with low opioid doses has minimal motor, sensory or sympathetic effects, with a subsequent lower side-effect liability than systemic therapy [90]. There can be dose-dependent motor blockade, urinary retention and skin numbness from the anesthetic added to the opioid. Since it is an invasive procedure requiring a long-term catheter, other non-invasive or one-time invasive procedures should be tried first.

When needed, we suggest putting an epidural catheter in on a trial basis. If found effective, a permanent epidural catheter can be implanted. The advantage of an epidural catheter is that local anesthetic agents have a higher margin of safety, while the disadvantage is the requirement of a larger volume of infusion necessitating an external pump with frequent refilling of medication [91]. With an intrathecal catheter a much lower volume is required and therefore, an internal pump can be placed (which requires refilling only about once a month).

### SURGICAL MANAGEMENT

If the above conservative measures fail to produce pain relief, surgical intervention may be necessary. An early employed technique was percutaneous aspiration of the cysts under ultrasound guidance [92]. Simple cyst aspiration can relieve pain temporarily, supporting the hypothesis that cyst distention can be a cause of pain [93]. Aspiration alone is inefficient because cysts will re-accumulate fluid due to an active chloride transport process. Percutaneous aspiration may be difficult secondary to the presence of multiple cysts; never knowing which cyst(s) is the major culprit for pain. Also, viscous cyst fluid may be difficult to aspirate. Rovsing, in 1911, originally performed surgical de-roofing and drainage of the cysts, and reported sustained reduction in renal size [94]. However, this procedure was subsequently abandoned in the 1960s due to reports that the procedure itself accelerated renal damage [95].

However, in the early 1980s He et al [96] and Zheng, Zhao and Wu [97] reported two separate series of cases where cyst decompression surgery resulted in excellent improvement in renal function as well as effective, lasting pain relief. This procedure was repeated by Elzinga et al, who reported that up to 80% of patients were pain free at 12 months postoperatively and 62% at 24 months after surgery [98]. Laparoscopic marsupialization of symptomatic polycystic kidney disease was reported by Brown et al in 1996 [99], a thorough extension of some earlier attempts at laparoscopic unroofing of both simple renal cysts and painful polycystic kidneys [100–104]. At 12 to 28 months after laparoscopic marsupialization, Brown and colleagues found that 50% of the polycystic patients were pain free. In contrast, 62% of patient with simple cysts were pain free. Subsequent studies demonstrated that laparoscopic surgery (decortication and marsupialization) may be effective in relieving pain in patients with ADPKD [105, 106].

In our own hands, laparoscopic cyst decortication (unroofing and collapse of cysts) in selected cases has been an effective modality to relieve pain. This laparoscopic procedure is restricted to patients who have severe pain attributed to cysts >5 cm in diameter. Usually the procedure is done unilaterally in a single sitting and the aver-

age number of cysts unroofed are between 30 and 70. Pain relief has been permanent in the majority of patients when followed for at least three years after the procedure. Renal function has not been improved nor has there been an accelerated decline in function as a result of this procedure. Earlier reports of improved kidney function [96, 97, 107] have not been supported by our personal observation or subsequent studies after laparoscopic or open intervention. Blood pressure transiently decreased for approximately two to four weeks after the laparoscopic surgery, but by one month post-procedure the blood pressure was back to baseline (which was elevated in most patients). Finally, in patients approaching ESRD, nephrectomy may be the only option for pain control, especially when renal function in the effected organ is minimal on radionuclide scanning. Nephrectomy also may be done in preparation for eventual transplant surgery, especially if the kidney has infected cysts or the massively enlarged kidneys represent a mechanical obstruction to allograft placement.

### RENAL DENERVATION

With the knowledge that visceral organ denervation is a routine consequence of kidney transplantation and leads to an insensate kidney with no alteration in renal function, a new approach has been developed by Valente et al (personal communication) for a laparoscopic transperitoneal approach for unilateral or bilateral renal denervation without the need for autotransplantation. The technique involves exposing the renal pedicle via the laparoscope and isolating the peri-arterial nerve fibers. Circumferential dissection, using an ultrasonic shear resection technique, divides the nerve fibers of the renal and intermesenteric plexi. Their preliminary report (in press) notes excellent results in the first ADPKD patient with refractory pain. Clinical application of renal nerve interruption awaits further study, especially comparing this procedure to laparoscopic cyst reduction approaches discussed above.

### PAIN RELATED TO POLYCYSTIC LIVER DISEASE

Pain, frequently expressed as chronic abdominal discomfort, related to liver cysts can be problematic and occurs across the spectrum of renal function (from normal to end-stage renal disease and persisting post-kidney transplant). While impairment of kidney function is a common consequence of ADPKD, liver function invariably remains normal despite massive polycystic liver disease. A recent study concluded that post-menopausal estrogen therapy selectively stimulated hepatic cyst enlargement in women with ADPKD who also had polycystic liver disease [108]. Hepatic cyst volume, but not renal

cyst volume, increased with estrogen therapy as compared to a control group of ADPKD women not taking estrogens. Abdominal symptoms became more pronounced in the ADPKD patients on estrogen therapy, presumably because of the extensive hepatic cystic disease. Non-pharmacologic and non-opioid pharmacology interventions tend to be ineffectual for pain/discomfort relief related to massive liver cysts. There appears to be a correlation between hepatic cyst size and number and the occurrence of refractory discomfort related to abdominal distention. When pain/discomfort becomes intolerable or evidence of malnutrition appears due to early satiety from cyst compression on the stomach, surgical approaches can be employed. Dyspnea is also noted as massive liver cysts can press on the diaphragm and this problem may tip the balance toward surgery.

Controversy exists with regards to the best management approach in patients with highly symptomatic polycystic liver disease and depends on the particular characteristics of each patient. Two approaches have received the most attention: fenestration techniques versus combined liver resection-fenestration [109–111]. Both laparoscopy and laparotomy have been used for the extensive fenestration technique. Because improvement in pain/discomfort perception appears to correlate with a reduction in computed tomography determination of hepatic cyst volume, the combined resection-fenestration maneuver offers the best chance to achieve the goal of pain reduction/relief [111]. Pain/discomfort relief occurs in almost all patients immediately post-operative. However, morbidity can occur in up to 50% of patients, mainly from biliary complications. Other problems in the above reports noted to occur (less frequently) include cholecystitis, small bowel obstruction, hemorrhage, pneumonia, thrombosis (Budd-Chiari syndrome), transient pleural effusion, and transient ascites. A warning note is offered with regards to posterior liver cysts, since an acute Budd-Chiari syndrome with subsequent death developed as a result of liver collapse after extensive fenestration of posterior cysts [112].

During a follow-up time extending out to 71 months in the above noted studies, overall pain/discomfort relief is to be expected in the short run. In the largest series published to date [111], selected patients with severe symptomatic polycystic liver disease and favorable anatomy did benefit from liver resection and fenestration with acceptable morbidity and mortality. The extent of hepatic resection and fenestration is important for long-term effectiveness of this procedure without a major increase in liver volume. However, recurrent symptoms did occur in a large percent of patients in the other noted studies [109, 110, 112], but generally milder than before surgery. An increase in liver volume has been observed in up to 40% of patients [110], and sequential computed tomography pre- and postoperative surgery suggests that



hepatic enlargement is due to expansion of existing cysts rather than the development of new cysts [111]. Surgical expertise is critical in determining the extent of hepatic resection and fenestration needed to achieve long-term effectiveness.

Orthotopic liver transplantation has been tried in selected cases when pain has become intolerable and every other modality of pain control has failed, resulting in limitations of daily activities as a consequence of hepatic cyst enlargement. While surgical complications are to be expected in this high-risk group, the one-year survival rate was 89% in the ADPKD group with polycystic liver disease. Excellent symptomatic relief and improved quality of life was documented in all surviving patients [113].

In summary, some patients may benefit from percutaneous cyst sclerosis or surgical fenestration, while others require combined liver resection-fenestration or even liver transplantation. Each individual requires a plan based on specific characteristics.

## CONCLUSION

A detailed thorough history, using charts to localize pain, is the most critical initial step in approaching pain management. Although severe pain is a common finding in patients with ADPKD, little has been written about the management of pain in this population. In the majority of these patients, pain can be successfully managed with currently available pain management techniques and careful elucidation of the underlying multifactorial causes of pain. Patients with complex pain problems may benefit from referral to a multidisciplinary pain center where a variety of medical, psychological and intervention therapies are available. As with any painful problem, knowledge of anatomy and physiology can help elucidate the diagnosis and lead to the most appropriate therapy.

## ACKNOWLEDGMENTS

We are indebted to the Polycystic Kidney Research Foundation for grant support since patients we investigated during an ADPKD Cohort Study also were treated for pain issues related to their PKD. Special thanks are given to Ms. Judi Hansjon for her excellent editorial assistance.

Reprint requests to Theodore I. Steinman, M.D., Renal Division, Department of Medicine, Beth Israel Deaconess Medical Center, 330 Brookline Avenue FD 220, Boston, Massachusetts 02215-5491, USA. E-mail: tsteinma@caregroup.harvard.edu

## REFERENCES

- GABOW PA: Autosomal dominant polycystic kidney disease, more than a renal disease. *Am J Kidney Dis* 16:403-413, 1990
- RAVINE D, GIBSON RN, WALKER RG, et al: Evaluation of ultrasonographic diagnostic criteria for autosomal dominant polycystic kidney disease 1. *Lancet* 343:824-827, 1994
- BENNETT W, ELZINGA L, BARRY J: Polycystic kidney disease: Diagnosis and management. *Hosp Pract* 4:61-72, 1992
- MARTINEZ JR, GRANTHAM JJ: Polycystic kidney disease: etiology, pathogenesis, and treatment. *Dis Mon* 41:693-765, 1995
- CHANDHOKE PS, TORRENCE RJ, CLAYMAN RV, ROTHSTEIN M: Acquired cystic disease of the kidney: A management dilemma. *J Urol* 147:969-974, 1992
- VANDEURSEN H, VAN DAMME B, BAERT J, BAERT L: Acquired cystic disease of the kidney analyzed by microdissection. *J Urol* 146:1168-1172, 1991
- KING BF, MATSUMOTO JS: Diagnostic imaging of renal cystic diseases (Chapt 8), in *Polycystic Kidney Disease*, edited by WATSON ML, TORRES VE, Oxford, Oxford University Press, 1996, pp 189-236
- CHAPMAN AB, RUBINSTEIN D, HUGHES R, et al: Intracranial aneurysms in autosomal dominant polycystic kidney disease. *N Engl J Med* 327:916-920, 1992
- SCHIEVINK WI, HUSTON J 3RD, TORRES VE, MARSH WR: Intracranial cysts in autosomal dominant polycystic kidney disease. *J Neurosurg* 83:1004-1007, 1995
- RYU S: Intracranial hemorrhage in patients with polycystic kidney disease. *Stroke* 21:291-294, 1990
- CHAPMAN AB, JOHNSON AM, GABOW PA: Intracranial aneurysms in patients with autosomal dominant polycystic kidney disease: How to diagnose and who to screen. *Am J Kidney Dis* 22:526-531, 1993
- MILUTINOVIC J, PHILIP J, FIALKOW P, et al: Clinical manifestations of autosomal dominant polycystic kidney disease in patients older than 50 years. *Am J Kidney Dis* 15:237-243, 1990
- MILUTINOVIC J, FIALKOW P, AGODOA L, PHILIP J: Autosomal dominant polycystic kidney disease symptoms and clinical findings. *Quart J Med (New Series L111)* 212: 511-522, 1984
- SEGURA JW, KING BF, JOWSEY SG, et al: Chronic pain and its medical and surgical management in renal cystic diseases (Chapt 19), in *Polycystic Kidney Disease*, edited by WATSON ML, TORRES VE, Oxford, Oxford University Press, 1996, pp 462-480
- ANSELL J, GEE W, BONICA J: Diseases of the kidney and ureter (Chapt 62), in *The Management of Pain* (vol 2, 2<sup>nd</sup> ed.), edited by BONICA J, Philadelphia, Lea & Febiger, 1990, pp 1232-1249
- AMMONS WS: Renal afferent input to thoracolumbar spinal neurons of the cat. *Am J Physiol* 250:R435-R443, 1986
- AMMONS WS: Bowditch Lecture. Renal afferent input to ascending spinal pathways. *Am J Physiol* 262:R165-R176, 1992
- NAM TS, BAIK EJ, SHIN YU, et al: Mechanism of transmission and modulation of renal pain in cats; Effects of transcutaneous electrical nerve stimulation of renal pain. *Yonsei Med J* 36:187-201, 1995
- SKLAR AH, CARUANA RJ, LAMERS JE, STRAUSSER GD: Renal infections in patients with adult polycystic kidney disease. *Am J Kidney Dis* 10:81-88, 1987
- BENNETT WM, ELZINGA LW: Clinical management of autosomal dominant polycystic kidney disease. *Kidney Int* 42(Suppl):S74-S79, 1993
- BENNETT WM, ELZINGA LW, PULLIAM JP, et al: Cyst fluid antibiotic concentration in autosomal dominant polycystic kidney disease. *Am J Kidney Dis* 6:400-404, 1985
- GRANTHAM JJ: Polycystic kidney disease: I. Etiology and pathogenesis. *Hosp Pract* 27:51-59, 1992
- SWEET R, KEANE WF: Perinephric abscess in patients with polycystic kidney disease undergoing chronic hemodialysis. *Nephron* 23: 237-240, 1979
- DALGAARD DZ: Bilateral polycystic disease of the kidneys. A follow up of 284 patients and their families. *Acta Med Scand* 328:12-33, 1957
- GRANTHAM JJ: The etiology, pathogenesis, and treatment of autosomal dominant polycystic kidney disease: Recent advances. *Am J Kidney Dis* 28:788-803, 1996
- ROVITCH L, LERMAN PH, DRABKIN J: Ruptured renal cysts in polycystic disease. *Urol* 7:60-61, 1976
- GABOW PA, DULEY I, JOHNSON AM: Clinical profiles of gross hematuria in autosomal dominant polycystic kidney disease. *Am J Kidney Dis* 20:140-143, 1992
- JOHNSON AM, GABOW PA: Identification of patients with autosomal dominant polycystic kidney disease at highest risk for end-stage renal disease. *J Am Soc Nephrol* 8:1560-1567, 1997
- JORDAN GH, BABCOCK NC, MOCNIK JJ, LYNCH DF: Pain control



- following renal infarction/ablation using continuous epidural combined anesthesia/analgesia. *J Urol* 130:861–862, 1983
30. TORRES VE, ERICKSON SB, SMITH LH, et al: The association of nephrolithiasis and autosomal dominant polycystic kidney disease. *Am J Kidney Dis* 11:318–325, 1988
  31. LEVINE E, GRANTHAM JJ: Calcified renal stones and cyst calcifications in autosomal dominant polycystic kidney disease. *Am J Radiology* 159:77–81, 1992
  32. DELANEY VB, ADLER S, BRUNS FJ, et al: Autosomal dominant polycystic kidney disease: Presentation, complications and prognosis. *Am J Kidney Dis* 5:104–111, 1985
  33. GRAMPAS SA, CHANDHOKE PS, FAN J, et al: Anatomic and metabolic risk factors for nephrolithiasis in patients with autosomal dominant polycystic kidney disease. *Am J Kidney Dis* 36:53–57, 2000
  34. TORRES VE, WILSON DM, HATTERY RR, SEGURA JW: Renal stone disease in autosomal dominant polycystic kidney disease. *Am J Kidney Dis* 22:513–519, 1993
  35. ANDERSON GA, DEGROOT D, LAWSON RK: Polycystic renal disease. *Urol* 42:358–364, 1993
  36. DELAKAS D, DASKALOPOULOS G, CRANIDIS A: Extracorporeal shockwave lithotripsy for urinary calculi in autosomal dominant polycystic kidney disease. *J Endourol* 11:167–170, 1997
  37. CHEN WC, LEE YH, HUANG JK, et al: Experience using extracorporeal shock-wave lithotripsy to treat urinary calculi in problem kidneys. *Urol Int* 51:32–38, 1993
  38. NG CS, YOST A, STREEM SB: Nephrolithiasis associated with autosomal dominant polycystic kidney disease: Contemporary urological management. *J Urol* 163:726–729, 2000
  39. ZWERGEL U, ZWERGEL T, ZIEGLER M: Effects of prostaglandins and prostaglandin synthetase inhibitors on acutely obstructed kidneys in the dog. *Urol Int* 47:64–69, 1991
  40. VAN LAECKE E, OOSTERLINCK W: Physiopathology of renal colic and therapeutic consequences. *Acta Urol Belgica* 62:15–18, 1994
  41. LUNDSTAM S, JONSON O, KIHIL B, PETTERSON S: Prostaglandin synthetase inhibition of renal pelvic smooth muscle in the rabbit. *Br J Urol* 57:390–393, 1985
  42. JOHNSTON HH, HERZOG JP, LAULER DP: Effect of prostaglandin E on renal hemodynamics, sodium and water excretion. *Am J Physiol* 231:939–944, 1967
  43. HETHERINGTON JW, PHILIP MH: Diclofenac sodium versus pethidine in acute renal colic. *Br Med J* 292:237–238, 1986
  44. OOSTERLINCK W, PHILIP NH, CHARIG C, et al: A double blind single dose comparison of intramuscular ketorolac, tromethamine and pethidine in the treatment of renal colic. *J Clin Pharmacol* 30:336–341, 1990
  45. MCINTIRE SC, RUBENSTEIN RC, GARTNER JC, et al: Acute flank pain and reversible renal dysfunction associated with nonsteroidal anti-inflammatory drug use. *Pediatrics* 92:459–463, 1993
  46. LEIN D, CLELLAND JA, KNOWLES C, JACKSON J: Comparison of effects of transcutaneous electrical stimulation of auricular, somatic and the combination of auricular and somatic acupuncture points on experimental pain threshold. *Physical Therapy* 69:671–678, 1989
  47. BENZON HT: Epidural steroid injections for low back pain and lumbosacral radiculopathy. *Pain* 24:277–295, 1986
  48. BREIVIK H, HESLA PE, MOLNAR I, LIND B: Treatment of chronic low back pain and sciatica: Comparison of caudal epidural injections of bupivacaine and methylprednisolone with bupivacaine followed by saline. *Adv Pain Res Ther* 1:927–932, 1976
  49. HALL D: Bad backs—uncovering the real problem: The Alexander technique sheds new light on a sore situation. *Lamp* 45:24–28, 1988
  50. TREVELYAN J: Alexander technique. *Nurs Times* 89:50–52, 1993
  51. BAEPLER A, KITKAT A: The Alexander technique. *Prof Nurse* 2: 222–224, 1987
  52. DENNIS RJ: Functional reach improvement in normal older women after Alexander technique instruction. *J Gerontol A Biol Sci Med Sci* 54:M8–M11, 1999
  53. STALLIBRASS C: An evaluation of the Alexander technique for the management of disability in Parkinson's disease—A preliminary study. *Clin Rehabil* 11:8–12, 1997
  54. HENRICH WL, AGODOA LE, BARRETT B, et al: Analgesics and the kidney: summary and recommendations to the Scientific Advisory Board of the National Kidney Foundation from an Ad Hoc Committee of the National Kidney Foundation. *Am J Kidney Dis* 27: 162–165, 1996
  55. HYIEK EM, HEIMAN H, SKATES FJ: Acetaminophen and other risk factors for excessive warfarin anticoagulation. *JAMA* 279:657–662, 1998
  56. SCHIODT FV, ROCHLING FA, CASEY DL, LEE WM: Acetaminophen toxicity in an urban county hospital. *N Engl J Med* 337:1112–1117, 1997
  57. WHITCOMB DC, BLOCK GD: Association of acetaminophen hepatotoxicity with fasting and ethanol use. *JAMA* 273:1845–1850, 1994
  58. SEIFERT CF, LUCAS DS, VONDRACEK TG, et al: Patterns of acetaminophen use in alcoholic patients. *Pharmacotherapy* 13:391–395, 1993
  59. CRYER B, FELDMAN M: Cyclooxygenase-1 and cyclooxygenase-2 selectivity of widely used nonsteroidal anti-inflammatory drugs. *Am J Med* 104:413–421, 1998
  60. GARELLA S, MATARESE RA: Renal effects of prostaglandins and clinical adverse effects of nonsteroidal anti-inflammatory agents. *Medicine* 63:165–181, 1984
  61. WOLFE MM, LICHTENSTEIN DR, SINGH G: Gastrointestinal toxicity of non-steroidal anti-inflammatory drugs. *N Engl J Med* 340:1888–1899, 1999
  62. GRIFFIN MR, RAY WA, SCHAFFNER W: Nonsteroidal anti-inflammatory drug use and death from peptic ulcer in elderly persons. *Ann Intern Med* 109:359–363, 1988
  63. FELDMAN M, McMAHON AT: Do Cyclooxygenase-2 inhibitors provide benefit similar to those of traditional nonsteroidal anti-inflammatory drugs, with less gastrointestinal toxicity. *Ann Intern Med* 132:134–143, 2000
  64. FELSON DT (Chair): Osteoarthritis: New insights. (NIH Conference). *Ann Intern Med* 133:726–737, 2000
  65. WERNICK R, CAMPBELL SM: Update in rheumatology. *Ann Intern Med* 132:125–133, 2000
  66. LIPSKY PE, BROOKS P, CROFFORD LJ, et al: Unresolved issues in the role of cyclooxygenase-2 in normal physiologic processes and disease. *Arch Int Med* 160:913–920, 2000
  67. SILVERSTEIN FE, FAICH G, GOLDSTEIN JL, et al: Gastrointestinal toxicity with Celecoxib vs nonsteroidal anti-inflammatory drugs for osteoarthritis and rheumatoid arthritis. The CLASS study: A randomized controlled trial. *JAMA* 284:1247–1255, 2000
  68. SWAN SK, RUDY DW, LASSETER KC: Effect of cyclooxygenase-2 inhibition on renal function in elderly persons receiving a low-salt diet. *Ann Intern Med* 133:1–9, 2000
  69. Prescriber's Letter. *Arthritis/Pain* 6:32, 1999
  70. Prescriber's Letter. *Arthritis/Pain* 6:32–33, 1999
  71. Prescriber's Letter. *Neuro/Psychiatry* 6:26, 1999
  72. EISENACH J, DETWEILER D, HOOD D: Hemodynamic and analgesic actions of epidurally administered clonidine. *Anesthesiology* 78: 277–287, 1993
  73. EISENACH JC, DeKOCK M, KLIMSCHA W: Alpha<sub>2</sub>-adrenergic agonists for regional anesthesia. A clinical review of clonidine (1984–1995). *Anesthesiology* 85:655–674, 1996
  74. STEINMAN TI: Pain management in polycystic kidney disease. *Am J Kidney Dis* 35:770–772, 2000
  75. YAO T: Acupuncture and somatic nerve stimulation: Mechanism underlying effects on cardiovascular and renal activities. *Scand J Rehabil Med* 29(Suppl):S7–S18, 1993
  76. MELZACK R, WALL PD: Pain mechanism, a new theory. *Science* 150:91, 1965
  77. LEWIS GT, KENYON JN: Physiological and psychological explanations for the mechanism of acupuncture for a treatment for chronic pain. *Soc Sci Med* 19:1367–1378, 1984
  78. POMERANZ B, CHIU D: Naloxone blockade of acupuncture analgesia: Endorphins implicated. *Life Sci* 19:1757–1762, 1976
  79. NAPPI G, FACCHINETTI F, LEGNANTE G, et al: Different releasing effects of traditional manual acupuncture and electro-acupuncture on proopiomelanocortin-related peptides. *Acupunct Electriher Res* 7:93–103, 1982
  80. CLEMENT-JONES V, McLOUGHLIN L, TOMLIN S, et al: Increased beta-endorphin but not met-enkephalin levels in human cerebro-

- spinal fluid after acupuncture for recurrent pain. *Lancet* 2:946-949, 1980
81. STAATS PS, KOST-BYERLY S: Celiac plexus blockade in a 7-year-old child with neuroblastoma. *J Pain Symptom Manage* 10:321-324, 1995
  82. FUGERE F, LEWIS G: Celiac plexus block for chronic pain syndromes. *Can J Anaesth* 40:954-963, 1993
  83. COLLAZOS: J, MAYO J, MARTINEZ E: Celiac plexus block as treatment for refractory pain related to sclerosing cholangitis in AIDS patients. *J Clin Gastroenterol* 23:47-49, 1996
  84. TANELIAN D, COUSINS MJ: Celiac plexus block following high-dose opiates for chronic noncancer pain in a four-year-old child. *J Pain Symptom Manage* 4:82-85, 1989
  85. HASTINGS RH, MCKAY WR: Treatment of benign chronic abdominal pain with neurolytic celiac plexus block. *Anesthesiology* 75:156-158, 1991
  86. MEGLIO M, CIONI B, ROSSI GF: Spinal cord stimulation in management of chronic pain. A 9-year experience. *J Neurosurg* 70:519-524, 1989
  87. MILES J, LIPTON S, HAYWARD M, et al: Pain relief by implanted electrical stimulators. *Lancet* 1:777-779, 1974
  88. KRAMES ES: Practical issues when using neuraxial infusion. *Oncology* 13:37-44, 1999
  89. FERRANTE FM: Neuraxial infusion in the management of cancer pain. *Oncology* 13:30-36, 1999
  90. STAATS PS: Neuraxial infusion for pain control. *Oncology* 13:58-62, 1999
  91. DUPEN S: Complications of neuraxial infusion in cancer patients. *Oncology* 13:45-51, 1999
  92. CHAPMAN AB, THICKMAN D, GABOW PA: Percutaneous cyst puncture in the treatment of cyst infection in autosomal dominant polycystic kidney disease. *Am J Kidney Dis* 16:252-255, 1990
  93. BENNETT WM, ELZINGA LW, GOLPER TA, BARRY JM: Reduction of cyst volume for symptomatic management of autosomal dominant polycystic kidney disease. *J Urol* 137:620-622, 1987
  94. ROVSING T: Treatment of multilocular renal cysts with multiple punctures. *Hospitalsid* 4:105-116, 1911
  95. BRICKER NS, PATTON JF: Renal function studies in polycystic disease of the kidneys with observations on the effects of surgical decompression. *N Engl J Med* 256:212-214, 1957
  96. HE S, AN S, JIANG H, et al: Cyst decapitating decompression operation in polycystic kidney: Preliminary report of 52 cases. *Chinese Med J* 93:773-778, 1980
  97. ZHENG K, ZHAO Z, WU Z: Analysis of 35 cases of polycystic kidneys. *Chung Hua Pi Niao Wai Ko Tsa Chih* 3:99-100, 1982
  98. ELZINGA L, BARRY J, TORRES V, et al: Cyst decompression surgery for autosomal dominant polycystic kidney disease. *J Am Soc Nephrol* 2:1219-1226, 1992
  99. BROWN JA, TORRES VE, KING BF, SEGURA JW: Laparoscopic marsupialization of symptomatic polycystic kidney disease. *J Urol* 156:22-27, 1996
  100. TEICHMAN JM, HULBERT JC: Laparoscopic marsupialization of the painful polycystic kidney disease. *J Urol* 153:1105-1107, 1995
  101. STOLLER ML, IRBY PB 3RD, OSMAN M, CARROLL PR: Laparoscopic marsupialization of a simple renal cyst. *J Urol* 150:1486-1488, 1993
  102. RUBENSTEIN SC, HULBERT JC, PHARAND D, et al: Laparoscopic ablation of symptomatic renal cysts. *J Urol* 150:1103-1106, 1993
  103. NIEH PT, BIHRLE W 3RD: Laparoscopic marsupialization of massive renal cyst. *J Urol* 150:171-173, 1993
  104. GUAZZONI G, MONTORSI F, BERGAMASCHI F, et al: Laparoscopic unroofing of simple renal cysts. *Urology* 43:154-159, 1994
  105. BARRY J, TEICHMAN JM, HULBERT JC: Role and long term results of laparoscopic decortication in solitary cystic and autosomal dominant polycystic kidney disease. *J Urol* 159:702-705, 1998
  106. ELASHRY OM, NAKADA SY, WOLF JS Jr, et al: Laparoscopy for adult polycystic kidney disease: A promising alternative. *Am J Kidney Dis* 27:224-233, 1996
  107. MILDAM JH, MAGEE JH, BUNTS RC: Evaluation of surgical decompression of polycystic kidneys by differential renal clearance. *J Urol* 90:144-149, 1963
  108. SHERSTHA R, MCKINLEY C, RUSS P, et al: Postmenopausal estrogen therapy selectively stimulates hepatic enlargement in women with autosomal dominant polycystic kidney disease. *Hepatology* 26:1282-1286, 1997
  109. GIGOT JF, JADOUL P, QUE F, et al: Adult polycystic liver disease: Is fenestration the most adequate operation for long-term management? *Ann Surg* 225:286-294, 1997
  110. KABBEJ M, SAUVANET A, CHAUVEAU D, et al: Laparoscopic fenestration in polycystic liver disease. *Br J Surg* 83:1697-1701, 1996
  111. QUE F, NAGORNEY DM, GROSS JB Jr, TORRES VE: Liver resection and cyst fenestration in the treatment of severe polycystic liver disease. *Gastroenterology* 108:487-494, 1995
  112. SORAVIA C, MENTHA G, GIOSTRA E, et al: Surgery for adult polycystic liver disease. *Surgery* 117:272-275, 1995
  113. SWENSON K, SEU P, KINKHABWALA M, et al: Liver transplantation for adult polycystic liver disease. *Hepatology* 28:412-415, 1998