

# Rapamycin Markedly Slows Disease Progression in a Rat Model of Polycystic Kidney Disease

Yunxia Tao, Jun Kim, Robert W. Schrier, and Charles L. Edelstein

*Division of Renal Diseases and Hypertension, University of Colorado Health Sciences Center, Denver, Colorado*

Increased tubular epithelial cell proliferation is a prerequisite for cyst formation and expansion in polycystic kidney disease (PKD). Rapamycin is a potent antiproliferative agent. The aim of the present study was to determine the effect of rapamycin on tubular cell proliferation, cyst formation, and renal failure in the Han:SPRD rat model of PKD. Heterozygous (Cy/+) and littermate control (+/+) male rats were weaned at 3 wk of age and then treated with rapamycin 0.2 mg/kg per d intraperitoneally or vehicle (ethanol) for 5 wk. Vehicle-treated Cy/+ rats had a more than doubling of kidney size compared with +/+ rats. Rapamycin reduced the kidney enlargement by 65%. Rapamycin significantly reduced the cyst volume density in Cy/+ rats by >40%. Blood urea nitrogen was 59% increased in vehicle-treated Cy/+ rats compared with +/+ rats. Rapamycin reduced the blood urea nitrogen to normal in Cy/+ rats. The number of proliferating cell nuclear antigen (PCNA)-positive cells per noncystic tubule was eightfold increased in vehicle-treated Cy/+ compared with +/+ rats. Rapamycin significantly reduced the number of PCNA-positive cells in noncystic tubules of Cy/+ rats. In addition, the number of PCNA-positive cells per cyst in Cy/+ rats was significantly reduced by rapamycin. In summary, in a rat model of PKD, rapamycin treatment (1) decreases proliferation in cystic and noncystic tubules, (2) markedly inhibits renal enlargement and cystogenesis, and (3) prevents the loss of kidney function.

*J Am Soc Nephrol* 16: 46–51, 2005. doi: 10.1681/ASN.2004080660

**A**utosomal dominant polycystic kidney disease (ADPKD) is the most common life-threatening hereditary disease in the United States. ADPKD accounts for approximately 5 to 10% of end-stage renal failure that requires dialysis and renal transplantation in the United States (1). There is no effective treatment for ADPKD.

The heterozygous Han:SPRD rat exhibits many of the features of ADPKD in humans, including (1) autosomal dominant inheritance; (2) relatively slow progression to end-stage renal failure with uremia, hypertension, and anemia; (3) bilateral renal involvement; (4) increased proliferation of renal cyst cells; and (5) more aggressive disease in males (2). The Han:SPRD rat is a suitable and well-documented animal model of PKD even though the defect is based on a mutation of a gene locus that is not a homologue of either the PKD1 or the PKD2 locus (3–6).

Human and experimental data provide strong evidence that abnormal proliferation in tubular epithelial cells plays a crucial role in cyst development and/or growth in PKD (7). Genetic manipulations that induce the proliferation of tubular epithelial cells in mice cause cysts to form in the kidney (8,9). Rapamycin is a Food and Drug Administration–approved immunosuppressive and powerful antiproliferative drug (10). In view of the importance of tubular cell proliferation in cyst formation

and the antiproliferative effects of rapamycin, we developed the hypothesis that rapamycin would reduce cyst formation and disease progression in PKD via inhibition of tubular cell proliferation.

## Materials and Methods

### Animals

The study was conducted in heterozygous (Cy/+) and normal littermate control (+/+) Han:SPRD rats. All of the normal rats and Cy/+ rats studied were male. The Cy/+ Han:SPRD rat develops clinically detectable PKD by 8 wk of age as evidenced by a doubling of kidney size and kidney failure compared with +/+ control rats (2,4). A colony of Han:SPRD rats was established in our animal care facility from a litter that was obtained from the Polycystic Kidney Program at the University of Kansas Medical Center. The study protocol was approved by the University of Colorado Health Sciences Center Animal Care and Use Committee. Rats had free access to tap water and standard rat diet.

### Experimental Protocol

Male Cy/+ and +/+ rats were weaned at 3 wk of age and then treated with rapamycin 0.2 mg/kg per d intraperitoneally or vehicle (ethanol) for 5 wk. Rapamycin was obtained from LC Laboratories (Woburn, MA), and a 1 mg/ml stock solution in 100% ethanol was kept at 4°C. At the end of the eighth week of age, rats were anesthetized by intraperitoneal injection of pentobarbital sodium (50 mg/kg body wt), and kidneys were removed and weighed. The left kidney was fixed in 4% paraformaldehyde in PBS for 120 min and then put into 70% ethanol and embedded in paraffin for histologic examinations.

### Cyst Volume Density

Hematoxylin-eosin–stained sections were used to determine the cyst volume density. This was performed by a reviewer who was blinded to

Received July 5, 2004. Accepted September 10, 2004.

Published online ahead of print. Publication date available at [www.jasn.org](http://www.jasn.org).

**Address correspondence to:** Dr. Charles L. Edelstein, Division of Renal Diseases and Hypertension, University of Colorado School of Medicine, Box C281, 4200 E. 9th Avenue, Denver, CO 80262. Phone: 303-315-8764; Fax: 303-315-4852; E-mail: [Charles.edelstein@uchsc.edu](mailto:Charles.edelstein@uchsc.edu)

the identity of the treatment modality, using point counting stereology (11). Areas of the cortex at 90, 180, and 270 degrees from the hilum of each section were selected to guard against field selection variation.

### Immunohistochemistry

Immunohistochemical detection of proliferating cell nuclear antigen (PCNA) staining was performed using an anti-PCNA antibody (Santa Cruz Biotechnology, Santa Cruz, CA; 1:50). The sections were incubated with alkaline-phosphatase-labeled polymer (DAKO EnVision System, Cat# K4016; DAKO, Carpinteria, CA) and visualized with the substrate chromogen fast red. Negative control sections showed no staining.

### Tubular Cell Proliferation

The number of PCNA-positive cells per tubule was counted using a Nikon Eclipse E400 microscope equipped with a digital camera connected to Spot Advanced imaging software (Version 3.5) by an observer who was blinded to the treatment modality. Noncystic tubules were defined as tubules that were  $<50 \mu\text{m}$  in diameter. At least 10 noncystic tubules or cysts in the cortex and medulla per sample were randomly selected and counted.

To avoid confusion between noncystic tubules and small cysts as well as potential changes in tubular cells lining massive cysts, PCNA-positive tubular cells were counted in "medium-sized cysts" of approximately  $250 \mu\text{m}$  in diameter. At least 10 cysts per sample in the cortex were randomly selected and counted.

### Chemistry

Serum urea nitrogen levels were measured using a Beckman auto-analyzer (Beckman Instruments, Fullerton, CA).

### Statistical Analyses

Nonnormally distributed data were analyzed by the nonparametric unpaired Mann-Whitney test. Multiple group comparisons were performed using a one-way ANOVA with posttest according to Newman-Keuls.  $P < 0.05$  was considered statistically significant. Values are expressed as means  $\pm$  SEM.

## Results

### Effect of Rapamycin on Body Weight, Two-Kidney/Total Body Weight Ratio, Cyst Volume Density, and Blood Urea Nitrogen

The body weight was 248 g in vehicle-treated  $+/+$  rats ( $n = 8$ ), 193 g in rapamycin-treated  $+/+$  rats ( $P < 0.01$  versus vehicle-treated  $+/+$ ;  $n = 6$ ), 260 g in vehicle-treated  $\text{Cy}/+$  rats ( $n = 9$ ), and 200 g in rapamycin-treated  $\text{Cy}/+$  rats ( $P < 0.01$  versus vehicle-treated  $\text{Cy}/+$ ;  $n = 5$ ). Thus rapamycin-treated  $+/+$  and  $\text{Cy}/+$  rats had a 22% decrease in body mass.

Despite the loss in body weight, all of the rats seemed healthy during the study. Two rats of a total of 16 rats that were treated with rapamycin died. These rats were not noted to be sick before death. None of a total of 17 vehicle-treated rats died.

Representative kidney sections of vehicle-treated  $+/+$ , vehicle treated  $\text{Cy}/+$ , and rapamycin-treated  $\text{Cy}/+$  rats, stained with hematoxylin-eosin, at the same magnification are demonstrated in Figure 1, A through C. The two-kidney/total body weight ratio was determined to correct for the lower body mass caused by the rapamycin. Two-kidney/total body weight ratio (%) was  $0.9 \pm 0.04$  in vehicle-treated  $+/+$  rats ( $n = 8$ ),  $0.9 \pm$

$0.03$  in rapamycin-treated  $+/+$  rats ( $n = 6$ ),  $2.0 \pm 0.1$  in vehicle-treated  $\text{Cy}/+$  rats ( $P < 0.001$  versus  $+/+$ ;  $n = 11$ ), and  $1.3 \pm 0.1$  in rapamycin-treated  $\text{Cy}/+$  rats ( $P < 0.001$  versus vehicle-treated  $\text{Cy}/+$  rats;  $n = 9$ ; Figure 1D).  $\text{Cy}/+$  rats had a more than doubling of kidney size compared with  $+/+$  controls. Rapamycin reduced the kidney enlargement by 65%.

Cyst volume density (CVD; %) was  $0.6 \pm 0.1$  in vehicle-treated  $+/+$  rats ( $n = 7$ ),  $46 \pm 4$  in vehicle-treated  $\text{Cy}/+$  rats ( $P < 0.001$  versus  $+/+$ ;  $n = 8$ ), and  $25 \pm 4$  in rapamycin-treated  $\text{Cy}/+$  rats ( $P < 0.01$  versus vehicle-treated  $\text{Cy}/+$ ;  $n = 5$ ; Figure 1E). Thus, rapamycin reduced the CVD by  $>40\%$ .

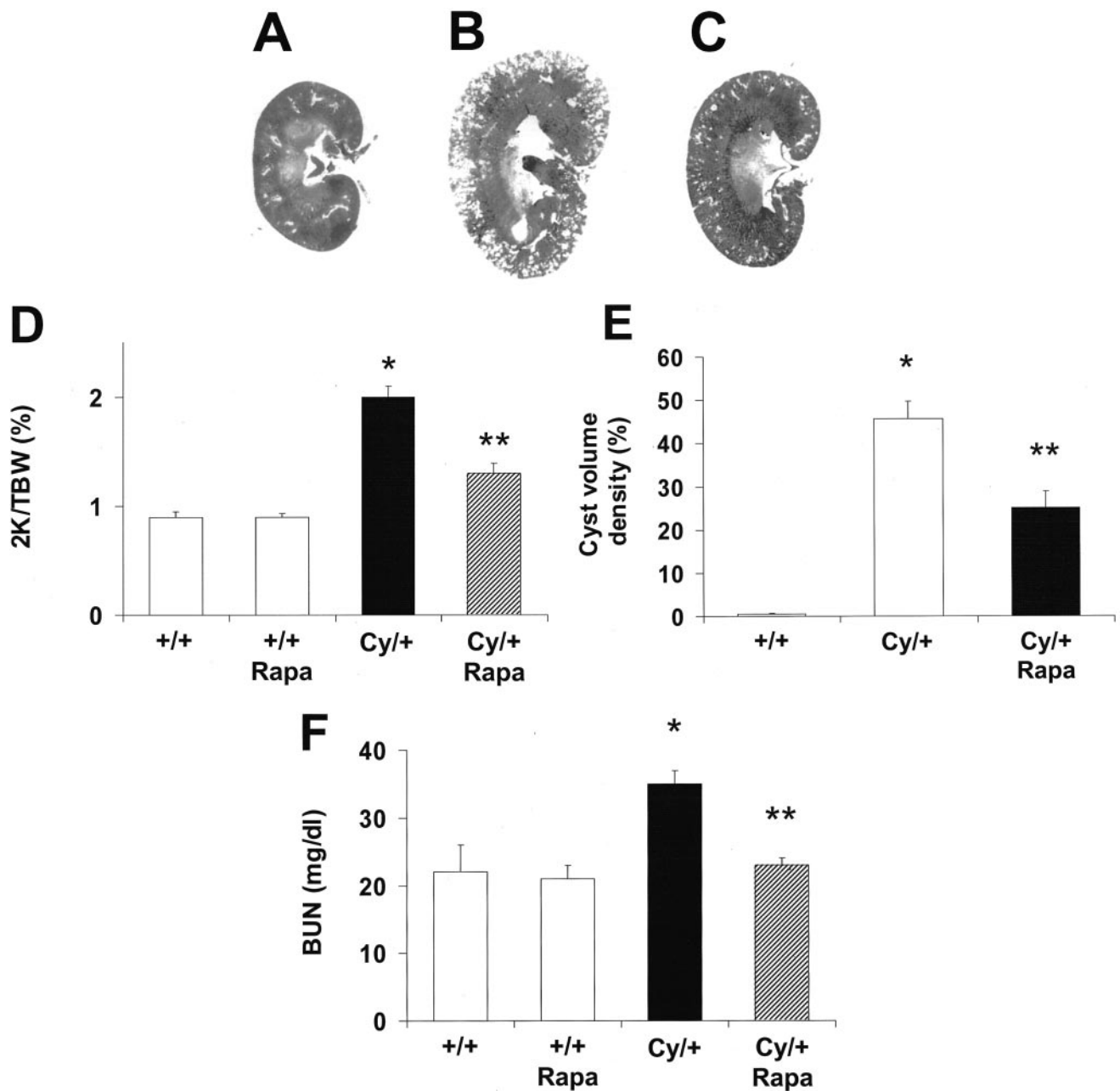
Blood urea nitrogen was  $22 \pm 4$  in vehicle-treated  $+/+$  rats ( $n = 5$ ),  $21 \pm 2$  in rapamycin-treated  $+/+$  rats ( $n = 5$ ),  $35 \pm 2$  in vehicle-treated  $\text{Cy}/+$  rats ( $P < 0.01$  versus vehicle- or rapamycin-treated  $+/+$ ;  $n = 6$ ), and  $23 \pm 1$  in rapamycin-treated  $\text{Cy}/+$  rats ( $P < 0.01$  versus vehicle-treated  $\text{Cy}/+$ , NS versus rapamycin-treated  $+/+$ ;  $n = 5$ ; Figure 1F). Thus, rapamycin completely prevented the increase in blood urea nitrogen in the  $\text{Cy}/+$  rats.

### Tubular Cell Proliferation

The number of PCNA-positive cells per tubule in noncystic tubules in the cortex and medulla was  $0.08 \pm 0.02$  in vehicle-treated  $+/+$  rats,  $0.17 \pm 0.04$  in rapamycin-treated  $+/+$  rats,  $0.65 \pm 0.1$  in vehicle-treated  $\text{Cy}/+$  rats ( $P < 0.05$  versus vehicle or rapamycin-treated  $+/+$ ), and  $0.2 \pm 0.1$  in rapamycin-treated  $\text{Cy}/+$  rats ( $P < 0.05$  versus vehicle treated, NS versus  $+/+$ ; Figure 2A). Representative pictures are shown in Figure 2, B through D. The number of PCNA-positive cells per cyst in the cortex was  $2.3 \pm 0.5$  in vehicle-treated  $\text{Cy}/+$  rats and  $0.4 \pm 0.3$  in rapamycin-treated  $\text{Cy}/+$  rats ( $P < 0.05$  versus vehicle-treated rats; Figure 3A). Representative pictures are shown in Figure 3, B and C.

## Discussion

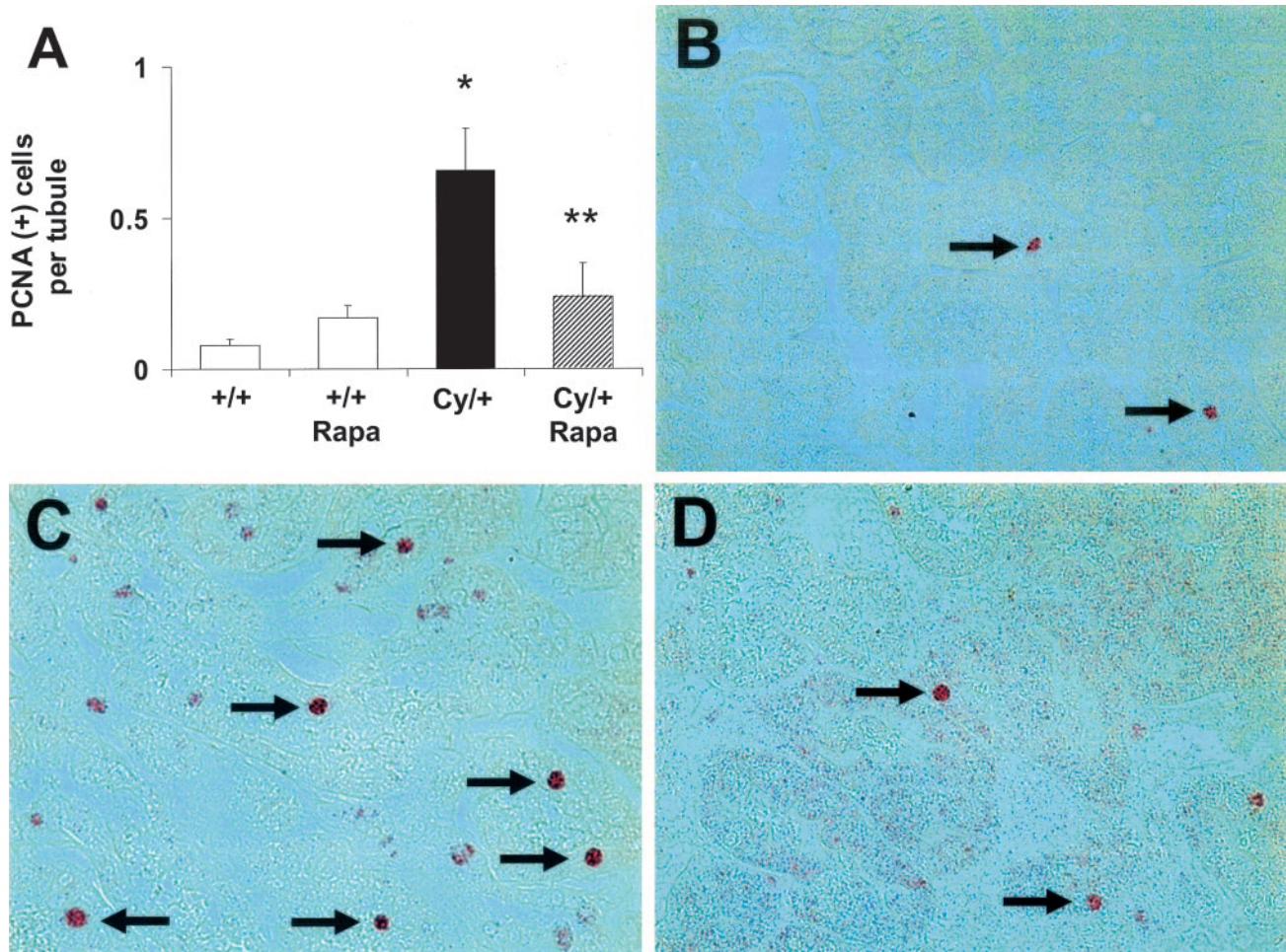
The bacterially-derived drug rapamycin, also known as sirolimus, specifically inhibits the mammalian target of rapamycin. The mammalian target of rapamycin is a serine threonine kinase that plays a central role in the regulation of cell proliferation, growth, differentiation, migration, and survival (12). Rapamycin is known to cause reduced cell growth, a reduced rate of cell-cycle progression, and reduced cell proliferation (13). Thus, rapamycin and its analogs CCI-779 and RAD001 have demonstrated promising anticancer activity and relatively mild side effects in phase I and II clinical studies (12). In addition, rapamycin inhibits proliferation of hematopoietic cells and is used to inhibit kidney transplant rejection. Because proliferation of tubular cells is one of the mechanisms of cyst enlargement in PKD, we examined the effect of rapamycin. In this regard, an EGF receptor tyrosine kinase inhibitor attenuated the cystic disease but not the renal failure in Han:SPRD rats (14). Another antiproliferative agent, paclitaxel, had no effect on PKD and increased mortality in Han:SPRD rats (15), whereas it had a remarkable effect on kidney size, renal function, and survival in congenital PKD (16). The immunosuppressive drug methylprednisolone retards interstitial fibrosis and the progression of PKD in the Han:SPRD rat (17).



**Figure 1.** Effects of rapamycin (Rapa) on the development of PKD in Han:SPRD rats. (A through C) Representative kidney sections, stained with hematoxylin-eosin, at the same magnification of vehicle-treated control (+/+; A), vehicle-treated heterozygous (Cy/+; B), and rapamycin-treated Cy/+ rats (C). (D) The two-kidney/total body weight ratio was unaffected by rapamycin in +/+ rats. Cy/+ rats had a more than doubling of kidney size compared with +/+ controls. Rapamycin reduced the kidney enlargement in Cy/+ rats by 65%. \* $P < 0.001$  versus +/+; \*\* $P < 0.001$  versus vehicle-treated Cy/+. (E) The cyst volume density was hugely increased in vehicle-treated Cy/+ rats. Rapamycin reduced the cyst volume density by >40%. \* $P < 0.001$  versus +/+, \*\* $P < 0.01$  versus vehicle treated Cy/+. (F) Blood urea nitrogen (BUN) was unaffected by rapamycin in +/+ rats. Cy/+ rats with polycystic kidney disease have kidney failure as indicated by a close to doubling in BUN. Rapamycin completely prevented the increase in BUN in the Cy/+ rats. \* $P < 0.01$  versus vehicle-treated and rapamycin-treated +/+ rats; \*\* $P < 0.01$  versus vehicle-treated Cy/+ rats, NS versus vehicle-treated and rapamycin-treated +/+ rats.

A consistent finding in the present study was that rapamycin decreased tubular cell proliferation in noncystic as well as cystic tubules. Although the proliferation index has been found to be consistently highest in cystic tubular epithelium, noncystic tubules from mice with polycystic kidneys (18) and Han:

SPRD rats (6) have higher proliferation rates than tubules from age-matched controls. In the present study, noncystic tubules in the cortex and medulla from Cy/+ rats with PKD had an eightfold increase in PCNA-positive cells compared with +/+ controls without PKD. These studies suggest that tubular cell



**Figure 2.** Tubular cell proliferation in noncystic tubules. (A) The number of proliferating cell nuclear antigen (PCNA)-positive cells per tubule in noncystic tubules in the cortex and medulla was increased in vehicle-treated Cy/+ rats compared with vehicle-treated and rapamycin-treated +/+ rats. Rapamycin-treated Cy/+ rats had significantly fewer PCNA-positive cells per tubule compared with vehicle-treated Cy/+ rats. \* $P < 0.05$  versus +/+ rats; \*\* $P < 0.05$  versus vehicle treated Cy/+ rats, NS versus +/+. (B) Vehicle-treated +/+ rats had relatively few PCNA-positive cells per tubule (arrows) compared with vehicle-treated Cy/+ rats (C; arrows). (D) Rapamycin decreased the number of PCNA-positive cells per tubule in Cy/+ rats (arrows).

proliferation precedes cyst formation in the Han:SPRD rat (6). Thus, rapamycin seems to decrease cyst formation, in part, by decreasing tubular cell proliferation in noncystic tubules.

Another finding of the present study was that rapamycin modestly decreased the body weight in both Cy/+ and control rats despite no apparent difference in food intake. Other studies in rats (19) and mice (20) have described weight loss caused by rapamycin. Long-term treatment with rapamycin has not been reported to cause weight loss in adults or children (21,22). The effect of lower doses of rapamycin and treatment for a longer period of time are the subject of ongoing animal studies.

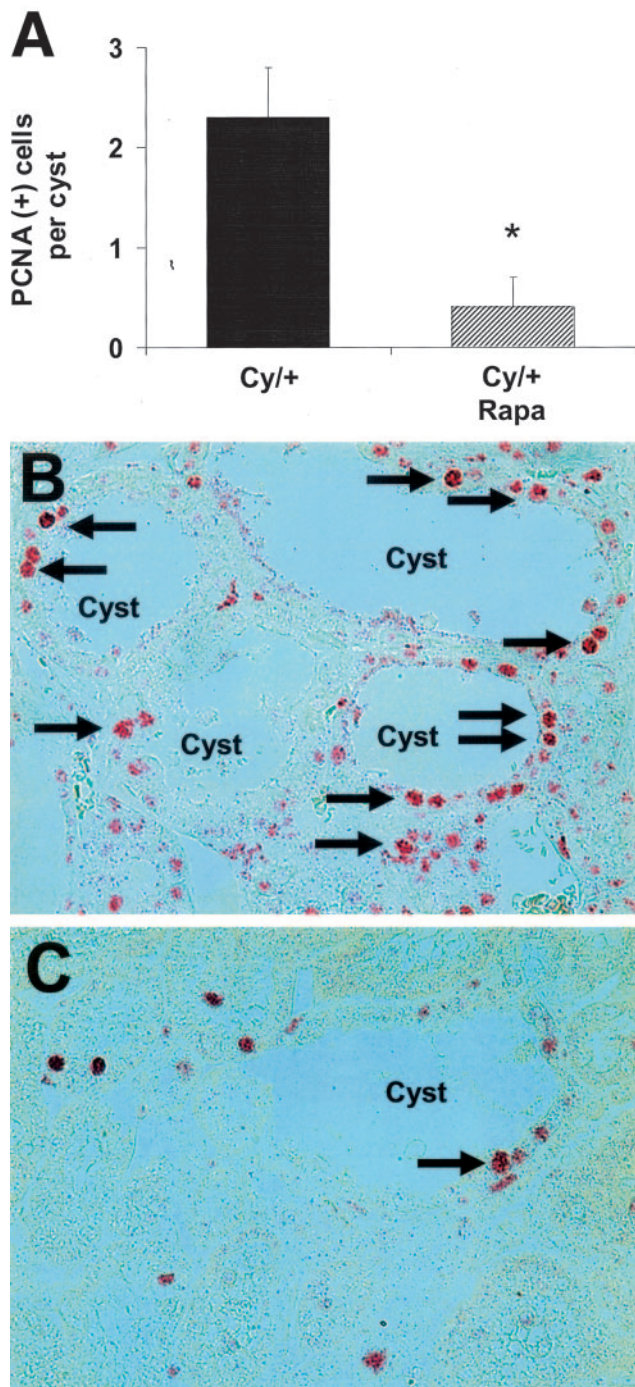
The rats were treated from a young age just after being weaned from their mothers. The rapamycin seemed to have no major side effects as the rats seemed healthy. Rapamycin has an excellent safety profile in both children and adults (21,22). In fact, transplant patients with nephrotoxic effects of calcineurin antagonists are often changed to rapamycin (23).

ADPKD is a significant cause of renal failure in adults. There

are currently no effective treatments. Rapamycin is a Food and Drug Administration–approved immunosuppressive drug to inhibit kidney transplant rejection (10). The ability of rapamycin to inhibit markedly cyst formation and prevent renal failure in rats demonstrates its potential to delay the onset of renal failure and subsequent dialysis in ADPKD patients. However, the usefulness of rapamycin and its analogs remains to be proved in other animal models of PKD and in randomized clinical trials in human ADPKD. In view of the absence of effective therapies in ADPKD and the safety of rapamycin as evidenced by long-term use in adults and children to prevent transplant rejection, future studies in other animal models of PKD and even future clinical studies are an exciting prospect.

### Acknowledgments

This work was supported by National Institutes of Health Grants DK56851 and DK34039 (section 3) to C.L.E. and DK52599 and DK34039 to R.W.S.



**Figure 3.** Tubular cell proliferation in cysts. (A) The number of PCNA-positive cells in tubular epithelial cells lining the cysts was significantly decreased by rapamycin (Rapa).  $*P < 0.05$  versus vehicle-treated Cy/+ rats. (B) Representative picture of the PCNA staining (arrows) in cysts of vehicle-treated Cy/+ rats. (C) Representative picture of the PCNA staining (arrows) in cysts of rapamycin-treated Cy/+ rats.

## References

- Fick-Brosnahan G, Ecker T, Schrier RW: Polycystic kidney disease. In: *Diseases of the Kidney and Urinary Tract*, Vol 2., 7th Ed., edited by Schrier RW, Philadelphia, Lippincott Williams & Wilkins, 2001, pp 547–588
- Cowley BD Jr, Gudapaty S, Kraybill AL, Barash BD, Harding MA, Calvet JP, Gattone VH2: Autosomal-dominant polycystic kidney disease in the rat. *Kidney Int* 43: 522–534, 1993
- Kranzlin B, Schieren G, Gretz N: Azotemia and extrarenal manifestations in old female Han:SPRD (cy/+ ) rats. *Kidney Int* 51: 1160–1169, 1997
- Schafer K, Gretz N, Bader M, Oberbaumer I, Eckardt KU, Kriz W, Bachmann S: Characterization of the Han:SPRD rat model for hereditary polycystic kidney disease. *Kidney Int* 46: 134–152, 1994
- Hocher B, Zart R, Schwarz A, Vogt V, Braun C, Thone-Reineke C, Braun N, Neumayer H, Koppenhagen K, Bauer C, Rohmeiss P: Renal endothelin system in polycystic kidney disease. *J Am Soc Nephrol* 9: 1169–1177, 1999
- Ramasubbu K, Gretz N, Bachmann S: Increased epithelial cell proliferation and abnormal extracellular matrix in rat polycystic kidney disease. *J Am Soc Nephrol* 9: 937–945, 1998
- Wilson PD: Polycystic kidney disease. *N Engl J Med* 350: 151–164, 2004
- Trudel M, D'Agati V, Costantini F: C-myc as an inducer of polycystic kidney disease in transgenic mice. *Kidney Int* 39: 665–671, 1991
- Schaffner DL, Barrios R, Massey C, Banez EI, Ou CN, Rajagopalan S, Aguilar-Cordova E, Lebovitz RM, Overbeek PA, Lieberman MW: Targeting of the rasT24 oncogene to the proximal convoluted tubules in transgenic mice results in hyperplasia and polycystic kidneys. *Am J Pathol* 142: 1051–1060, 1993
- Fingar DC, Blenis J: Target of rapamycin (TOR): An integrator of nutrient and growth factor signals and coordinator of cell growth and cell cycle progression. *Oncogene* 23: 3151–3171, 2004
- Cowley BD Jr, Rupp JC, Muessel MJ, Gattone VH2: Gender and the effect of gonadal hormones on the progression of inherited polycystic kidney disease in rats. *Am J Kidney Dis* 29: 265–272, 1997
- Huang S, Houghton PJ: Targeting mTOR signaling for cancer therapy. *Curr Opin Pharmacol* 3: 371–377, 2003
- Schmelzle T, Hall MN: TOR, a central controller of cell growth. *Cell* 103: 253–262, 2000
- Torres VE, Sweeney WE Jr, Wang X, Qian Q, Harris PC, Frost P, Avner ED: EGF receptor tyrosine kinase inhibition attenuates the development of PKD in Han:SPRD rats. *Kidney Int* 64: 1573–1579, 2003
- Martinez JR, Cowley BD, Gattone VH2, Nagao S, Yamaguchi T, Kaneta S, Takahashi H, Grantham JJ: The effect of paclitaxel on the progression of polycystic kidney disease in rodents. *Am J Kidney Dis* 29: 435–444, 1997
- Woo DD, Miao SY, Pelayo JC, Woolf AS: Taxol inhibits progression of congenital polycystic kidney disease. *Nature* 368: 750–753, 1994
- Gattone VH2, Cowley BD Jr, Barash BD, Nagao S, Takahashi H, Yamaguchi T, Grantham JJ: Methylprednisolone retards the progression of inherited polycystic kidney disease in rodents. *Am J Kidney Dis* 25: 302–313, 1995
- Trudel M, Barisoni L, Lanoix J, D'Agati V: Polycystic kidney disease in SBM transgenic mice: Role of c-myc in disease induction and progression. *Am J Pathol* 152: 219–229, 1998
- Lieberthal W, Fuhro R, Andry CC, Rennke H, Abernathy VE, Koh JS, Valeri R, Levine JS: Rapamycin impairs recov-

- ery from acute renal failure: Role of cell-cycle arrest and apoptosis of tubular cells. *Am J Physiol Renal Physiol* 281: F693–F706, 2001
20. Ravikumar B, Vacher C, Berger Z, Davies JE, Luo S, Oroz LG, Scaravilli F, Easton DF, Duden R, O’Kane CJ, Rubinsztein DC: Inhibition of mTOR induces autophagy and reduces toxicity of polyglutamine expansions in fly and mouse models of Huntington disease. *Nat Genet* 36: 585–595, 2004
  21. Tejani A, Alexander S, Ettenger R, Lerner G, Zimmerman J, Kohaut E, Briscoe DM: Safety and pharmacokinetics of ascending single doses of sirolimus (Rapamune, rapamycin) in pediatric patients with stable chronic renal failure undergoing dialysis. *Pediatr Transplant* 8: 151–160, 2004
  22. Ettenger RB, Grimm EM: Safety and efficacy of TOR inhibitors in pediatric renal transplant recipients. *Am J Kidney Dis* 38: S22–S28, 2001
  23. Flechner SM: Minimizing calcineurin inhibitor drugs in renal transplantation. *Transplant Proc* 35: 118S–121S, 2003

**Access to UpToDate on-line is available for additional clinical information  
at <http://www.jasn.org/>**