Abstract

Kidney International
Volume 64 Issue 3 Page 1035 - September 2003
doi:10.1046/j.1523-1755.2003.00185.x

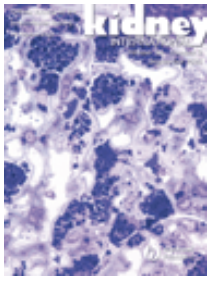

Renal structure in early autosomal-dominant polycystic kidney disease (ADPKD): The Consortium for Radiologic Imaging Studies of Polycystic Kidney Disease (CRISP) cohort[1]

Arlene B. Chapman, Lisa M. Guay-Woodford, Jared J. Grantham, Vicente E. Torres, Kyongtae T. Bae, Deborah A. Baumgarten, Philip J. Kenney, Bernard F. King, Jr., James F. Glockner, Louis H. Wetzel, Marijn E. Brummer, W. Charles O'Neill, Michelle L. Robbin, William M. Bennett, Saulo Klahr, Gladys H. Hirschman, Paul L. Kimmel, Paul A. Thompson, and J. Philip Miller

Renal structure in early autosomal-dominant polycystic kidney disease (ADPKD): The Consortium for Radiologic Imaging Studies of Polycystic Kidney Disease (CRISP) cohort

Background. Autosomal-dominant polycystic kidney disease (ADPKD) is characterized by gradual renal enlargement and cyst growth prior to loss of renal function. Standard radiographic imaging has not provided the resolution and accuracy necessary to detect small changes in renal volume or to reliably measure renal cyst volumes. The Consortium for Radiologic Imaging Studies in Polycystic Kidney Disease (CRISP) is longitudinally observing ADPKD individuals using high-resolution magnetic resonance (MR) imaging to determine if change in renal and cyst volumes can be detected over a short period of time, and if they correlate with decline in renal function early in disease.

Methods. Standardization studies were conducted in phantoms and four subjects at each participating clinical center. After, in the full-scale protocol, healthy ADPKD individuals 15 to 45 years old with creatinine clearance>70 mL/min underwent standardized MR renal imaging, renal iothalamate clearance, comprehensive clinical evaluation, and determination of 24-hour urinary albumin and electrolyte excretion. Stereology was used from T1-weighted images to quantify renal volume, and region-growing thresholding was used from T2-weighted images to determine cyst volume. Renal structures were evaluated in relation to demographic, clinical, and biochemical variables using means/medians, standard deviations, and Pearson correlations.

Results. Reliability coefficients for MR renal and cyst volume measurements in phantoms were 99.9% and 89.2%, respectively. In

the full-scale protocol, 241 ADPKD individuals (145 women and 96 men) were enrolled. Total renal, cyst, and % cyst volume were significantly greater in each decade group. Hypertensive individuals demonstrated greater renal, cyst, and % cyst volume than normotensive subjects. Age-adjusted renal ($r = -0.31$, $P < 0.0001$), cyst ($r = -0.36$, $P < 0.0001$), and % cyst volume ($r = -0.35$, $P < 0.0001$) were inversely related to glomerular filtration rate (GFR). Age-adjusted renal volume ($r = 0.42$, $P < 0.0001$), cystic ($r = 0.39$, $P < 0.0001$, and % cyst volume ($r = 0.41$, $P < 0.0001$) were related with urinary albumin excretion.

Conclusion. MR measures of renal and cyst volume are reliable and accurate in patients with ADPKD. ADPKD is characterized by significant cystic involvement that increases with age. Structure (renal and cyst volume) and function (GFR) are inversely related and directly related with the presence of hypertension and urinary albumin excretion in individuals with normal renal function.

References | Full Text Article | PDF [860KB]

Key words:
autosomal-dominant polycystic kidney disease
magnetic resonance imaging
renal volume
cyst volume
renal function

Search

Received for publication December 10, 2002 and in revised form April 3, 2003
Accepted for publication May 5, 2003

Affiliations
Departments of Medicine (Renal Division) and Radiology, University of Alabama at Birmingham, Birmingham, Alabama; Emory University School of Medicine, Atlanta, Georgia; University of Kansas Medical Center, Kansas City, Kansas; The Mayo Foundation, Rochester, Minnesota; Washington University, St. Louis, Missouri; the Division of Biostatistics, Washington University, St. Louis, Missouri; Northwest Renal Clinic, Portland, Oregon; and the National Institutes of Health, NIDDK, Bethesda, Maryland
Correspondence
Reprint requests to Arlene B. Chapman, M.D., Emory University School of Medicine, 1639 Pierce Drive, WMB 338, Atlanta, GA 30322. E-mail: arlene_chapman@emory.org

To cite this article
Chapman, Arlene B., Guay-Woodford, Lisa M., Grantham, Jared J., Torres, Vicente E., Bae, Kyongtae T., Baumgarten, Deborah A., Kenney, Philip J., King, Bernard F., Glockner, James F., Wetzel, Louis H., Brummer, Marijn E., O'Neill, W. Charles, Robbin, Michelle L., Bennett, William M., Klahr, Saulo, Hirschman, Gladys H., Kimmel, Paul L., Thompson, Paul A. & Miller, J. Philip (2003) Renal structure in early autosomal-dominant polycystic kidney disease (ADPKD): The Consortium for Radiologic

Forward Links to Citing Articles

- Franck A. Belibi, Gail Reif, Darren P. Wallace, Tamio Yamaguchi, Lincoln Olsen, Hong Li, George M. Helmkamp, Jr., and Jared J. Grantham . Cyclic AMP promotes growth and secretion in human polycystic kidney epithelial cells[1]. *Kidney International* 66: 3, 964-973.

  Online publication date: 1-Sep-2004.

  Abstract | References | Full Text Article | PDF

- Bernard F. King, Vicente E. Torres, Marijn E. Brummer, Arlene B. Chapman, Kyongtae T. Bae, James F. Glockner, Kraisthith Arya, Joel P. Felmlee, Jared J. Grantham, Lisa M. Guay-Woodford, William M. Bennett, Saulo Klahr, Gladys H. Hirschman, Paul L. Kimmel, Paul A. Thompson, J. Phillip Miller, and the Consortium for Radiologic Imaging Studies of Polycystic Kidney Disease (CRISP) . Magnetic resonance measurements of renal blood flow as a marker of disease severity in autosomal-dominant polycystic kidney disease[1]. *Kidney International* 64: 6, 2214-2221.

  Online publication date: 1-Dec-2003.

  Abstract | References | Full Text Article | PDF

Imaging Studies of Polycystic Kidney Disease (CRISP) cohort[1].
Kidney International **64** (3), 1035-1045.
doi: 10.1046/j.1523-1755.2003.00185.x